

## Original Article

# Histopathology of gills of silver carp, *Hypophthalmichthys molitrix* (valenciennes) exposed to lead

Zafar Iqbal\* and Arfa Khawar

Department of Zoology, University of the Punjab, Qaud-E-Azam Campus, Lahore-54590, Pakistan.

(Article history: Received: July 29, 2013; Revised: September 21, 2013)

### Abstract

The present study was aimed to investigate the effects of lead on histology of gills of silver carp, *Hypophthalmichthys molitrix*. The fish was exposed to three doses / treatments of lead (T1=6mg/l, T2=12mg/l, T3=18mg/l) for five weeks. In trial T1, the gills showed degeneration and fusion of secondary lamellae, dilation of blood vessel, proliferation of mucous cells and infiltration of erythrocytes. In trial T2, primary lamellae had swollen tips and severe hyperplasia on lamellar epithelium. Secondary lamellae were curled and fused to form club shaped structure and lamellar blood vessels were engorged. The cyst formation was followed by lamellar fusion. Haemorrhages and complete loss of secondary lamellae and epithelial degeneration was prominent. In Trial 3, acute atrophy and hypertrophy in the secondary lamellae was most evident feature. While vacuolation and severe degeneration of the basal epithelium of primary lamellae were prominent. Severe hyperplasia, necrosis and complete loss of secondary lamellae were the most serious effects of lead toxicity on gills. This study has shown that the heavy metal even in the lowest concentration has very toxic effects on the gills of silver carp, depending on the concentration of doses applied.

**Key words:** Lead toxicity, silver carp, gill pathology, hyperplasia, atrophy, hypertrophy.

**To cite this article:** IQBAL, Z. AND KHAWAR, A., 2013. Histopathology of gills of silver carp, *Hypophthalmichthys molitrix* (valenciennes) exposed to lead. *Punjab Univ. J. Zool.*, 28(2): 61-67.

## INTRODUCTION

Gills are the vital organs for exchange of gases, excretion and osmoregulation process in fish. They are delicate and are easily damaged by exposure to aquatic pollution. Fish has ability to regulate the heavy metal dose to some extent, but beyond that bioaccumulation occurs (Heath, 1991). Gills of the fish respond to the chemicals in water by alterations in their morphology and physiology. This change is not pollutant specific but depends on the dose of the pollutant and the exposure time (Evans, 1987; Lindesjoo and Thulin, 1994; Karan *et al.*, 1998; Azmat *et al.*, 2012). Gills are good indicator of any alteration in fish histology produced as a result of exposure to heavy metals, especially when metal is present as in dissolved form in water. Histological alterations in tissues serve as reliable biomarkers to evaluate the fish health status when exposed to metal (Wester and Canton, 1991). These changes occur either as a response to the toxicant intake or as an adaptive strategy to a sudden environmental change (Mohamed, 2009). Gills serve as an important organ for

histopathological studies as they are present externally and become vulnerable to the pollutants and comprise the 60% area of fish body (Roberts, 1989).

Certain heavy metals are potential toxicants and cause severe damage to the fish gills (Kakuta and Murachi, 1997; Wenderlaarbonga, 1997). Lead mostly affects the primary and secondary lamellar epithelium of gills and also causes infiltration of erythrocytes and collapse of blood capillaries in them. Many studies on fishes exposed to lead such as, Mallatt (1985) on *Oreochromis niloticus*; Wilson and Laurent (2002) on *Cyprinus carpio*; Gbem *et al.* (2001) on *Clarias gariepinus*, Khan *et al.* (2011) on African catfish and Kumar *et al.* (2011) on tiger shrimp, *Penaeus monodone* reported multiple changes in gills such as; damage of gill tips and lamellar fusion, disintegration of gill lamellae; metal accumulation in gills and liver, extensive hyperplasia of lamellar epithelium, deformed gill tips and prominent inter lamellar spaces. Two recent studies on metal toxicity in commercial fishes from the rivers Ravi and river Indus in Pakistan by Jabeen *et al.* (2012), Shakir *et al.*,

2013 and Jabeen and Chaudhry (2013) have also reported the accumulation of heavy metals in liver, kidney and gills. The present study was conducted to evaluate the toxic effects of lead on the structure of gills of silver carp, *Hypophthalmichthys molitrix* under laboratory conditions.

## MATERIALS AND METHODS

### Experimental design and Lead treatment of fish:

The experiment was conducted in glass aquaria (24x24x30 inches, 280 L capacity) and a flow through system. Aeration was maintained through aerator (Daivo pump NS 4200) and 25% water was changed daily to avoid contamination. The experimental set up was maintained in Fish Disease and Health Management laboratory. The water quality parameters were recorded prior to experimentation. Experimental trials for the histopathological study were applied every 7 days (one week) and continued for 35 days (five weeks).

Two hundred fingerlings of silver carp (BW 24.0-32.0gm, TL 12.7- 15.8cm) were brought from Punjab University Research Fish Farm. Prior to experiments fish were acclimatized for one week in lab. Twenty fishes were used in each treatment. Three replicates were maintained for each test and one aquarium served as a control. Three treatment groups referred to three different concentrations of lead nitrate (T1, 6mg/l; T2, 12mg/l and T3, 18mg/l of  $Pb(NO_3)_2$ ). Five percent stock solution of lead nitrate was prepared in distilled water and its further dilutions were made for each treatment T1, T2, and T3 with the help of following formula:  $m_1V_1 = m_2V_2$ . Three dilutions were transferred to the respective aquaria at flow rate of 2ml/sec. The control group was not given  $Pb(NO_3)_2$ .

To observe the toxic effects of lead on gill of silver carp, on every 7th day, fish from control and each of three treatments were dissected. To examine toxic effects on gills, histology was done according to standard histological technique. Gills were collected with sharp razor blade and their sections of about 1cm were cut and fixed in Bouin's fluid for 24 hours. After the routine tissue processing sections were cut at 5-6 $\mu$  and stained with haematoxylin and eosin. Photomicrographs of represent active sections were taken with

microscope swift M3300-d equipped with canon EOS 500 camera.

## RESULTS

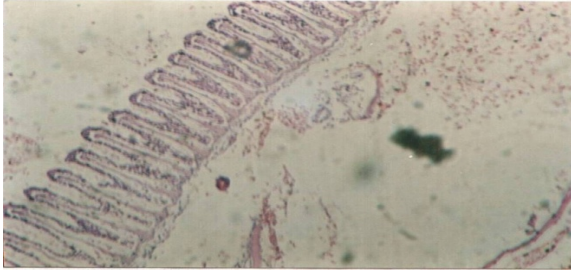
The histological changes in the gills of silver carp exposed to three concentrations of  $Pb(NO_3)_2$  are shown in the Figs. 2.1 to 4.4. There were significant pathological changes in the gills of the treated fish as compared to control fish. In T1, at the end of week; separation and degeneration of gill epithelium, damage and fusion of tips of secondary lamellae were observed (Fig. 2). Mucus membrane lining the outer surface of secondary lamellae was disintegrated. During week 2, mucus cells discharged into the interlamellar space and settled down at the basal layer and secondary lamellae were curled (Fig. 2.1). At week 3, the mucus cells shifted towards the tips of secondary lamellae and infiltration of erythrocytes was also significant in primary lamellae (Fig. 2.2).

Four weeks exposure of gills to lead, caused regeneration of mucosal lining on secondary lamellae. The tips of gill were severally damaged and became flat instead of being rounded (Fig. 2.3). This trend continued till week 5, when severe changes in tips of secondary lamellae were observed which had eroded epithelium (Fig. 2.4).

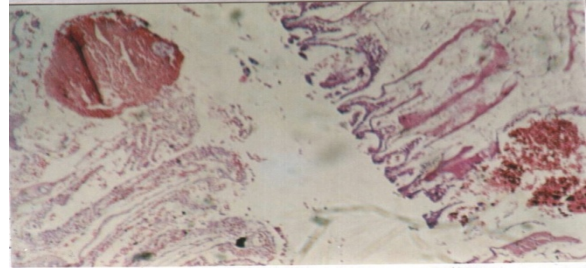
In T2, severe pathological changes were observed at the end of week 1, including swollen tips of the gills. The space between secondary lamellae became widened (Fig. 3). At week 2, curling, fusion and elongation of secondary lamellae, even epithelial disintegration was prominent resulting in loss of tissue free space (Fig. 3.1). At week 3, acute epithelial hyperplasia and lamellar atrophy; fusion, deformation and elongation of several secondary lamellae were clear. Engorged blood vessels with red blood cells appeared bright red (Fig. 3.2).

At week 4, partial loss of secondary lamellae, epithelial disintegration of gills causing thinning and curling of secondary lamellae was prominent. Oedematous changes were also observed in some primary lamellae. (Fig.3.3).

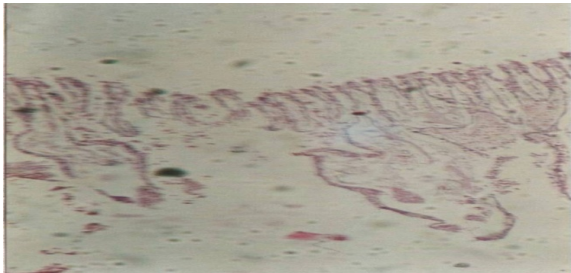At week 5, haemorrhages of central blood cord followed by intense epithelial hyperplasia resulted in complete obliteration of intact morphology of secondary lamellae which appeared thread like delicate and curled (Fig. 3.4).



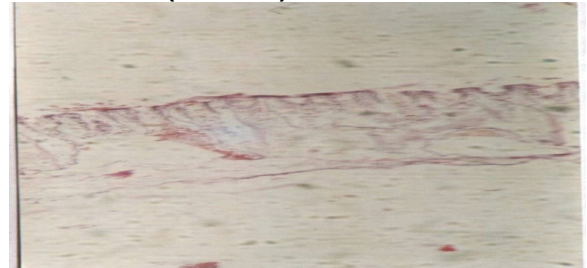**Figure 1** A normal gill of silver carp showing primary and secondary lamellae. (H+E x20)



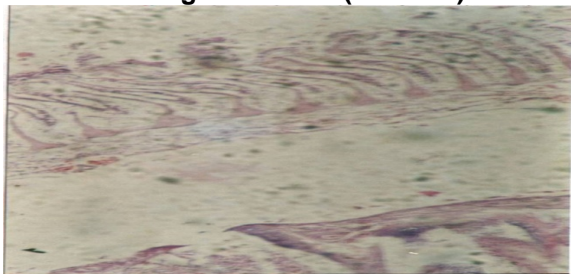
**Figure 2.3** T1(week 4): Fusion of secondary lamellae, regeneration and coagulation of mucosal layer. (H+E x20)



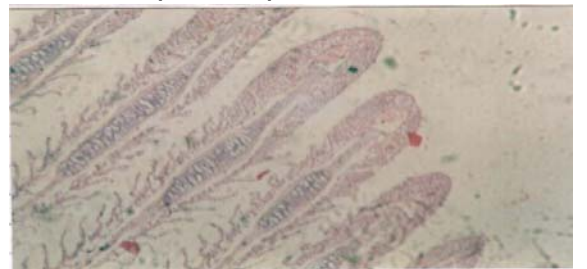
**Figure 2** T1 (week 1): Degeneration and fusion of some secondary lamellae and damage at the tips of gill filament. (H+E x10)



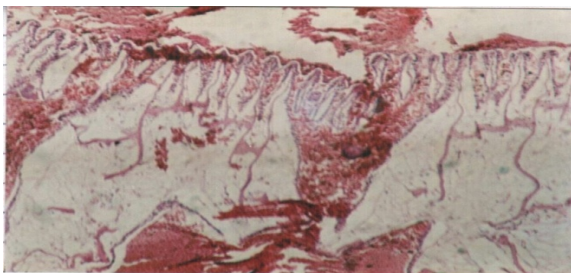
**Figure 2.4** T1 (week 5): Deformed lamellar tips and thin layer of slime on the surface of secondary lamellae. (H+E x10)



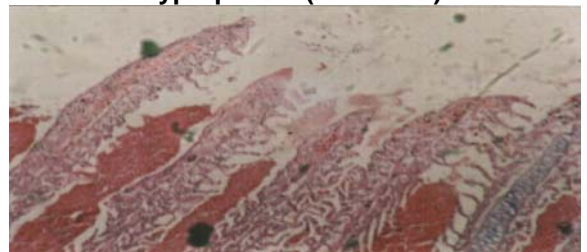
**Figure 2.1**T1 (week 2): Dilation of central blood vessel, aggregation of mucous cells at the basal membrane. (H+E x20)



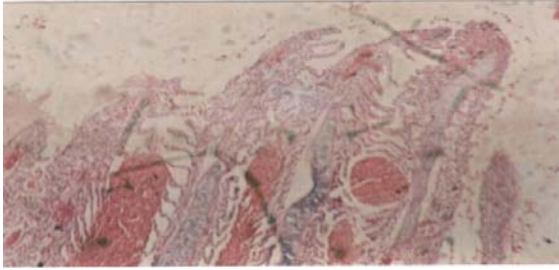
**Figure 3** T2 (week 1) Tips of primary lamellae are swollen with fusion of secondary lamellae and hyperplasia. (H+E x400)



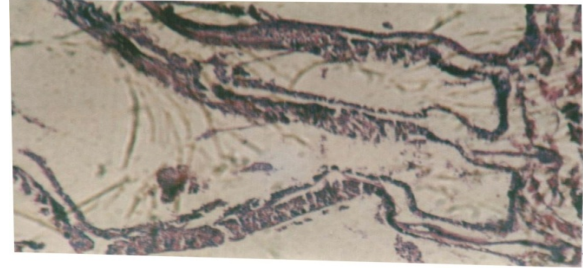
**Figure 2.2** T1 (week 3): Proliferation of mucous cells in the interlamellar space, Infiltration of erythrocytes.(H+E x20)



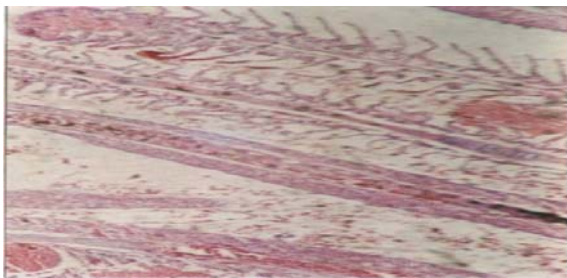
**Figure 3.1** T2 (week 2) Curling and fusion of secondary lamellae, engorged lamellar blood vessels and shortening of secondary lamellae. (H+E x400)



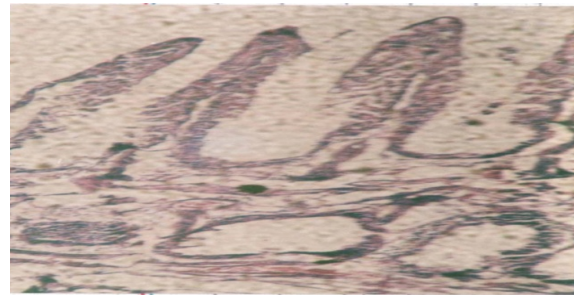
**Figure 3.2T2 (week 3)** Deformed gill tips, acute hyperplasia, cyst formation and lamellar fusion. Engorgement is seen in central vessel of gill with erythrocytes in it. (H+E x400)



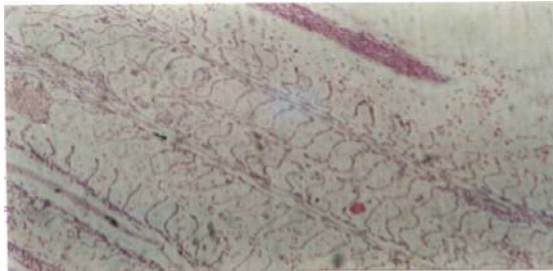
**Figure 4 T3 (week 1)** Acute atrophy and hypertrophy in the secondary lamellae and vacuolation in the basal layer of epithelium of primary lamellae. (H+E x400)



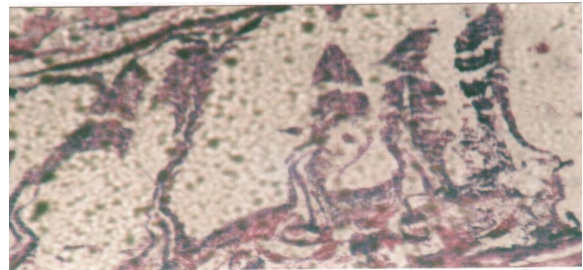
**Figure 3.3 T2 (week 4)** Partial loss, thinning and curling of secondary lamellae, edema in gill filaments, increased discharge of inflammatory cells. (H+E x200)



**Figure 4.1T3 (week 2)** Increased vacuolation in the basal layer of primary lamellae, severe degenerative epithelium of primary lamellae are prominent. (H+E x200)



**Figure 3.4 T2 (week 5)** Haemorrhages due to severe hyperplasia, complete loss of secondary lamellae and epithelial degeneration. (H+E x200)

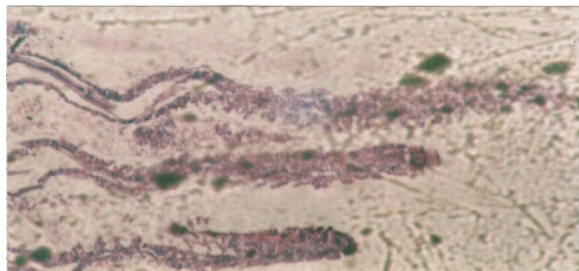


**Figure 4.2T3 (week 3)** Severe hyperplasia and necrosis of primary lamellae and complete loss of secondary lamellar structure are visible. (H+E x200)

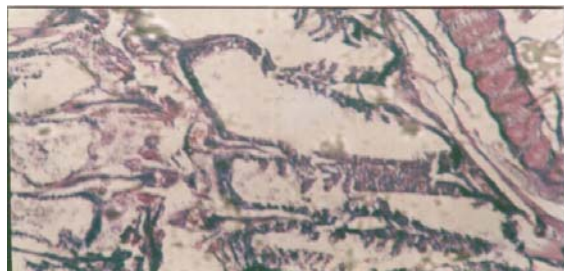At week 4, the mucous lining of the secondary lamellae was completely lost and lamellae appeared as indistinct mass of cellular constituents (Fig. 4.3). At week 5, large scale severe pathological changes and increased distance between secondary lamellae and lacuna was frequently seen (Fig. 4.4).

In T3, severe damage to the gills was seen in all five weeks. Atrophy was continuously observed at every week. At week 1, acute atrophy and hypertrophy in secondary lamellae occurred accompanied by vacuolation in the basal layer. Rupture of epithelial lining and secondary lamellae became indistinct (Fig. 4). Vacuolation becomes more prominent at week 2, and big lacuna appeared in the basal layer.

Damage leading to degeneration of epithelial lining in secondary lamellae was clear (Fig. 4.1). Severe hyperplasia and necrosis and complete loss of lamellar structure was observed at week 3 (Fig.4.2).



**Figure 4.3 T3 (week 4) Total loss of protective mucous lining and ruptured epithelium of secondary lamellae, intense hypertrophy and abnormal elongation of primary lamellae. (H+E x200)**



**Figure 4.4 T3 (week 5) Deformities in gill basal attachment layer, lacuna and epithelial degeneration and increased distance between secondary lamellae are seen.(H+E x200)**

## DISCUSSION

The gill histology of silver carp, treated with lead nitrate revealed significant gill pathology. All three treatments of lead to silver carp, exhibited various levels of damage in the gill structure.

In T1, epithelial lifting, deformation of tips of gill filaments and hyperplasia were observed accompanied by fusion of secondary lamellae at certain locations. Similar results were put forward by Khan *et al.* (2011) in *C. batrachus* exposed to lead nitrate. Mallate (1985)

also observed disintegration in secondary lamellae and gill tips in *O. niloticus* exposed to lead. In T2, initial changes in gills included swelling of gills tips; fusion and curling of secondary lamellae, epithelial hyperplasia and severe deformation, The oedematous changes were similar for each exposure but were most prominent at week 3 and 4. The sloughing off mucous cells eventually inhabits the interlamellar space to prevent the adherence of toxicants to the gill surface (Powell *et al.*, 1992). Alterations in gills in terms of oedema of primary and secondary lamellae are probably results of high permeability of blood vessels in response to the metal exposure (Olurin *et al.*, 2006). In T3, large scale wear and tear was observed followed by intense epithelial hyperplasia, vacuolation in primary lamellae, acute necrosis and hypertrophy of secondary lamellae which eventually lead to complete loss of lamellar structure.

Necrosis is irreversible and alterations in the gills occur in response to exposure of toxicants/pollutants (Takashima and Hibiya, 1995). Lamellar necrosis was highest in T3 at week 5 which may eventually cause respiratory stress to fish. The cellular degenerative changes, atrophy and lamellar necrosis disrupt the ion exchange and respiratory mechanisms in fish (Dutta *et al.*, 1993).

The severe pathological changes observed in gills of silver carp in the present study might have probably occurred as a homeostatic response to exposure to lead to prevent their entry into the gills or as a reaction to the metal. Lamellar fusion most frequently seen (in T2 and T3) may result in reduction of lamellar surface area for gas exchange. Vacuolation is characterized by increased non tissue space which leads to the diminished oxygen supply within the gills. Hinton and Lauren (1990) concluded that the lamellar epithelium is most highly affected by sub-lethal exposure of heavy metals which result in lesions. The histological changes in gills provide a barrier for contaminants entrance into the body as they increase the distance between the external environment and circulatory system (Fernades and Mazon, 2003). Olojo *et al.* (2005) reported similar observations in the gills of *C. gariepinus* exposed to various concentrations of lead. Khan *et al.* (2011) reported that in African catfish exposed to sub-lethal concentration of lead results in fusion, curling and epithelial lifting of secondary lamellae and degeneration of lamellar epithelium and infiltration of

erythrocytes. Kumar *et al.* (2011) found that gill lamellae undergo necrosis and epithelial lifting, vacuolation and damage of pillar cells and epithelial proliferation. Jabeen and Chaudhry (2013) reported desquamation of lamellar epithelium, hypertrophy of epithelial cells, lifting up of lamellar epithelium, intraepithelial oedema, hyperplasia and haemorrhage in the gill filament. Our results are comparable to the findings reported in these studies. The histopathological changes in the gill tissue serve as bio-markers of toxic effects of heavy metal on fish health and presence of these metals in water. It is concluded that lead is a potential toxicant to fish such as silver carp. Its presence in water cause severe pathological changes in the gills of fish, which results in the loss of basic histological structure and physiological function of the gills. Such condition eventually results in serious health issues for the fish.

## REFERENCES

- AZMAT, H., JAVED, M. AND JABEEN, G., 2012. Acute toxicity of aluminium to the fish (*Catla catla*, *Labeo rohita* and *Cirrhina mrigala*). *Pak. Vet. J.*,**32**: 85-87.
- DUTTA, H.M., RICHMONDS, C. AND ZENO, T., 1993. Effects of diazinon on the gills of blue gill sunfish, *Lepomis macrochirus*. *J. Environ. Pathol. Toxicol. Oncol.*,**12**: 219-227.
- EVANS, D.H., 1987. The fish gill: site of action and model for toxic effects of environmental pollutants. *Environ. Health Perspect.*,**71**: 47-58.
- FERNADES, M.N. AND MAZON, A.F., 2003. Environmental pollution and fish gill morphology. In: *Fish adaptations in field* (ed. B.G. Kapoor). Science Publishers, London, pp. 203-231.
- GBEM, T.T., BALOGUN, J.K., LAWAL, F. AND ANNUNE, P.A., 2001. Trace metal accumulation in *Clarias gariepinus* (Teugels) exposed to sublethal levels of tannery effluent. *Sci. Total. Environ.*,**271**: 1-9.
- HEATH, A.G., 1991. *Water pollution and fish physiology*, Lewis Publishers, Boca Raton, Florida, USA, 359 p.
- HINTON, D.E. AND LAUREN, D.J., 1990. Liver structural alterations accompanying chronic toxicity in fishes: Potential biomarkers of exposure. Biomarkers of environmental contamination. Lewis Publishers, Boca Raton, Florida, pp. 51-65.
- JABEEN, F. AND CHAUDHRY, A.S., 2013. Metal Uptake and Histological Changes in Gills and Liver of *Oreochromis mossambicus* inhabiting Indus River. *Pak. J. Zool.*,**45**: 9-18.
- JABEEN, G., JAVED, M., AND AZMAT, H., 2012. Assessment of heavy metals in the fish collected from the River Ravi, Pakistan. *Pak. Vet. J.*,**32**: 107-111.
- KAKUTA, I. AND MURACHI, S., 1997. Physiological response of carp, *Cyprinus carpio*, exposed to raw sewage containing fish processing wastewater. *Environ. Toxicol. Water Quality*,**12**: 1-9.
- KARAN, V., VITOROVIC, S., TUTUNDZIC, V. AND POLEKSIC, V., 1998. Functional enzymes activity and gill histology of carp after copper sulphate exposure and recovery. *Ecotoxicol. Environ. Saf.*,**40**: 49-55.
- KHAN, H.A., SIKDAR-BAR, M., KAMLESH, B., WANI, A.A. AND PERVAIZ, P.A., 2011. Lead Nitrate Induced Histopathological Changes in the Gills of the African *Clarias Batrachus*. *J. Applied Sci. Res.*,**7**: 1081-1086.
- KUMAR, S.P., SHARADHAMMA, A.S., DANIEL, S.G. AND MOHAMED, M.A., 2011. Impact of lead nitrate on the gills of tiger shrimp, *Penaeus monodon* exposed to sub lethal concentrations leading to histological changes. *Int. J. Current Res.*,**3**: 45-48.
- LINDESJOO, E. AND THULIN, J., 1994. Histopathology of skin and gills of fish in pulp mill effluents. *Dis. Aquat. Org.*,**18**: 81-93.
- MALLATT, J., 1985. Fish gill structural changes induced by toxicants and other irritant: a statistical review. *Can. J. Fish*,**42**: 630-648.
- MOHAMED, F.A.S., 2009. Histopathological studies on *Tilapia zillii* and *Solea vulgaris* from Lake Qarun, *Egypt. W. J. Fish. Mar. Sci.*,**1**: 29-39.
- OLOJO, E.A.A., OLURIN, K.B., MBAKA, G. AND OLUWEMINO, A.D., 2005. Histopathology of the gill and liver tissues of the African catfish *Clarias gariepinus* exposed to lead. *Afr. J. Biotechnol.*,**4**: 117-122.
- OLURIN, K.B., OLOJO, E.A.A., MBAKA, G., AND AKINDELE, A., 2006.

- Histopathological responses of the gill and liver tissues of *Clarias gariepinus* fingerlings to the herbicide, glyphosate. *Afr. J. Biotechnol.*, **5**: 2480-2487.
- POWELL, M.D., SPEARE, D.J. AND BURKA, J.F. 1992. Fixation of mucus on rainbow trout (*Onchorhynchus mykiss* Walbaum) gills for light and electron microscopy. *J. Fish Biol.*, **41**: 813-824.
- ROBERTS, R.J., 1989. *Fish Pathology*(ed. 2<sup>nd</sup>.). Bailliere Tindall, London.
- SHAKIR, H.A., CHAUDHRY, A.S. AND QAZI, J.I., 2013. Impact of anthropogenic activities on physico-chemical parameters of water and mineral uptake in *Catla catla* from river Ravi, Pakistan. *Environ. Monit. Assess.*, **185**(3): 2833–2842
- TAKASHIMA, F AND HIBIAY, T., 1995, *An Atlas of fish physiology of normal and pathological features* (ed. 2<sup>nd</sup>). Kodansha, Tokyo.
- WENDERLAARBONGA, S.E., 1997. The Stress Response in fish. *Physiological Review*, **77**: 591-625.
- WESTER, P.W. AND CANTON, J.H., 1991. The usefulness of histopathology in aquatic toxicity studies. *Compar. Biochem. Physio.(C)*., **100**:115-117.
- WILSON, M AND LAURENT, P., 2002. Fish gill morphology: inside out. *J. Exp. Zool.*, **293**: 192-213.