



Research Article

# Turmeric Plays Protective Role against Paraben Induced Hepatic and Renal Lesions in Albino Mice

Chaman Ara<sup>1\*</sup>, Asmatullah<sup>1</sup>, Zainab Riaz<sup>1</sup>, Memoona<sup>1</sup>, Asma Chaudhary<sup>2</sup>, Shagufta Andleeb<sup>2</sup>

<sup>1</sup>Department of Zoology, Faculty of Life Sciences, University of the Punjab, Lahore, Pakistan

<sup>2</sup>Department of Zoology, University of Education, Lahore, Pakistan

### Article History

Received: October 05, 2019

Revised: December 17, 2019

Accepted: January 08, 2020

Published: January 10, 2020

### Authors' Contributions

CA and Asmatullah conceived, executed and supervised the study. CA wrote the manuscript. ZR and Memoona conducted the experiments. SA did histopathology and slide labelling.

### Keywords

Butyl paraben (BP), Turmeric, hepatic toxicity, Nephrotoxicity, Histology

**Abstract** | Preservatives have been used since prehistoric times and today is a recurring topic in world debate. Paraben is among the top class preservatives used in food, pharmaceutical agents, drinks, beautifying agents and numerous different items. So purpose of study was to determine the possible hepatic and nephrotoxic effects of Butyl paraben in mice and to explore the possible curative and protective impacts of turmeric. Fifty mice randomly divided in five groups, i.e. Control, dose group (BP), dose and antidote group (BP+AD), vehicle control group (VC) and antidote group (AD). A sub lethal concentration containing 15ug/g B.W of BP was given with and without turmeric orally, dissolved in corn oil, used as vehicle too. Dissections were made on 31<sup>st</sup> day, twenty-four hours after the last dose administration. Results showed that continuous administration of butyl paraben (BP) had decreased the organs weight as compared to control. Regarding biochemical parameters results had shown an increased enzymatic level of alanine transaminase (ALT), aspartate transaminase (AST), alkaline phosphatase (ALP) and a significant increase in bilirubin levels in BP group. Significant raised patterns were recorded for urea and creatinine in BP intoxicated mice against control. Histological defects observed were necrosis, pyknosis, increased sinusoidal spaces, portal hypertension, glomerulosclerosis, abnormal vascular pole in liver and kidney respectively. But when turmeric powder was coadministered with BP, these damages were reversed to a great extent. So, this study has proved the protective role of turmeric against toxicity induced by BP in female albino mice.

**Novelty Statement** | Curcumin, an active component of turmeric along with its proven anti-fungal and antimicrobial activities also detoxify Paraben (suspected car-cinogen and endocrine disruptor) instigated damages.

**To cite this article:** Ara, C., Asmatullah, Riaz, Z., Memoona, Chaudhary, A. and Andleeb, S. 2020. Turmeric plays protective role against paraben induced hepatic and renal lesions in albino mice. *Punjab Univ. J. Zool.*, 35(1): 07-12. <https://dx.doi.org/10.17582/journal.pujz/2020.35.1.07.12>

## Introduction

From previous few years, concern has aroused regarding possible unfriendly impacts of chemical additives on hepatic and renal functions. Parabens are much highlighted name of commercial industry as they are used in daily used products of humans and we all humans are exposed to this compound in one way or the other (e.g. food products,

cosmetics and pharmaceuticals preservatives (Fransway *et al.*, 2019). They are stable at broad range of temperature, effective over vast scale pH range and retain anti-bacterial, anti-fungal and anti-microbial properties (Alam *et al.*, 2014; Abbas *et al.*, 2010). They are soluble in water to prepare a powerful fixative for liquefied phase, have no noticeable odor and taste.

Most commonly these compounds are absorbed inside body by oral intake and dermal applications. They are metabolized inside body by liver enzymes and byproducts

**Corresponding author:** Dr. Chaman Ara  
[dr.chamanara@yahoo.com](mailto:dr.chamanara@yahoo.com)

are excreted out in bile and urine (Nowak *et al.*, 2018). Toxicity and effectiveness of parabens mainly hang on the length of alkyl chain substituent. Greater the length of alkyl chain of substituent greater the toxicity of paraben so the order is as follows: methyl paraben < ethyl paraben < butyl paraben < propyl paraben and so on. It is a very common constituent of more than 90 percent cosmetic and food products where it is mainly used as preservative (Zhang *et al.*, 2017).

Humans are primarily exposed to this compound via processed food like jams, jellies, canned fruits and beverages etc. (Boberg *et al.*, 2016). Dermal application of cosmetic products like lipsticks, eye shadows, perfumes, foundations etc. are also one of main sources of absorption of this compound in human body. As females are more exposed towards cosmetic products so their exposure to this compound is greater in comparison to males (Giulivo *et al.*, 2016). Massive consumption magnifies the BP level with respect to concentration subjected to time. After absorption by skin or oral ingestion BP partly breaks down into PHBA and alcohol. Some intestinal enzyme also participates in this process.

Liver is the main detoxification center of body, it plays an important role in production of anti-oxidants and maintains the metabolic mechanism of body. Raised production levels of AST, ALP and ALT are critical indicators of liver abnormality caused due to any exogenous or endogenous factor like toxic compound or virus etc. (Abbas *et al.*, 2010; Boberg *et al.*, 2010). BP is known to cause damaging effects on oxidizing organs like liver and kidney. BP may cause increased number of free radicals in hepatic cells and may lower the concentration of glutathione, superoxide dismutase and ascorbic acid (Watkins *et al.*, 2015).

Spices and herbs are one of the most primitive therapeutic agents known to mankind. *Curcuma longa* (turmeric) is one of the cheap and easily available spice. Curcumin is an active and most important component present inside turmeric. It has many anti-oxidative and anti-carcinogenic characters (Nabavi *et al.*, 2012; Embuscado *et al.*, 2015; Shi *et al.*, 2019). The basic working mechanism of turmeric is to increase the amount of anti-oxidants inside body, it also decreases the amount of reactive oxygen species thus it can lower the oxidative stress efficiently as also reported by (Ahmida, 2012; Shi *et al.*, 2019). Other scientific researchers i.e. El-Mahalaway (2015) have also reported turmeric as an effective antidote against the induced toxicity of poisonous compounds. Curcumin is the best ingredient of turmeric that naturally boosts up immunity and has anti-microbial and anti-fungal properties.

The main research goal of this study is to indicate all the possible toxic and damaging effects of BP on liver and kidney at 15µg/g B.W. Turmeric was used as an antidote to investigate its therapeutic potential against the probable induced toxicity by butyl paraben. As our work was on mammalian model so results can be extrapolated to human beings.

## Materials and Methods

### Experimental animals

Research was carried on Swiss Webster mice (*Mus musculus*), reared in the animal house of Zoology Department, University of the Punjab, Lahore, Pakistan. Light cycle was kept constant i.e. 14/10h light/dark cycle. Temperature 27±2 °C was maintained for the experiment with 40-50% factor of humidity. Readymade chick feed pellets were used (Feed No 10, National feeds, Lahore, Pakistan). Healthy growth of mice was ensured by adding supplements during husbandry. Feed and water were given ad libitum. Randomly selected one month old (weighing 10-15g) animals were placed in five groups. Each group contained 10 mice. The study was properly done in keeping the view of ethical guidance of local committee of University of the Punjab, Lahore.

### Chemicals

N-butyl paraben of analytical grade was purchased from Sigma Aldrich, Martin Dow Marker Specialties (Pvt.) Ltd D-7, Shaheed-e-Millat Road, Karachi-75350, Pakistan. Raw turmeric was purchased from local market, washed, dried and grinded to get raw turmeric powder.

### Experimental design

50 randomly selected prepubertal mice were divided in 5 groups and placed in separate cages. Group I, control animals were maintained without any treatment. Animals of group II designated as BP, was orally exposed to BP 0.1 ml solution having desire amount of dose (15µg/g B.W). 0.1 ml of BP solution along with 0.1 ml of turmeric solution was given to group III (BP+AD). 0.1ml of corn oil was orally administered to vehicle control (VC) group IV. While group V (AD) only administrated with turmeric solution (0.04mg/0.1ml) (Hawlings and Kalma, 2017). Mice were treated with single dose daily for 30 days. After completion of treatment, animals were sacrificed following procedures and guidelines by Ethical committee on animal care and experimentation of University of the Punjab, Lahore, Pakistan. Required viscera were dissected out and blood extracted through cardiac puncture under deep chloroform anaesthesia.

### Determination of biochemical parameters

10ml serum collection tubes were used to collect blood sample and were maintained at room temperature for 30 min. Samples were centrifuged for 10 min to obtain

serum at 4 °C. Bayer's kits were used according to the prescribed protocols by the manufacturer. Total proteins, bilirubin, aspartate transaminase, alanine transaminase, alkaline phosphatase, creatinine and urea concentrations be assayed.

#### Morphology and morphometric observations

The livers and kidneys of dissected mice of all groups were examined. Morphological analysis was done by using Labomed microscope USA. Their physical appearance and shape was noticed. For morphometric observations kidneys and livers were weighed on digital balance. Width and length of liver and kidney was measured accurately with the help of digital Vernier calipers.

#### Histopathology of kidney and liver tissues

For histopathology, livers and kidneys were kept in formalin and then tissues were transferred to series of alcoholic concentrations i.e. 70%, 80%, 90% and then 100% for dehydration. For the clearance of tissues for paraffin embedding, xylene was used. Embedding of tissues was done in liquid paraffin wax. Small thin sections of 5 microns were cut by rotatory microtome. Tissue sections having paraffin wax were transferred to a glass slide and dried at 40 °C. For Staining wax was removed by treating with xylene. Followed by rehydration, sequence of alcohol washes was reversed i.e. from higher to lower grade. Hematoxylin and eosin were used for staining nucleus and cytoplasm respectively and slides were viewed under light microscope, SWIFT MD3500. High mega pixel camera was used for taking microphotographs

#### Statistical analysis

Data was analyzed using SPSS version 21. Means  $\pm$  SEM was recorded. Analysis of variance (ANOVA) was used to determine the mean differences between various groups. A difference between the groups was considered at  $p \leq 0.05$  level of significance.

## Results and Discussion

#### Morphological and morphometric analyses

Analysis of livers showed decreased Weight and size in BP group against control. Same findings were in case of kidneys, significantly reduced weight were recorded in BP treated group in comparison with control. Organ weight in vehicle was lowered but not significantly different from control. Turmeric has shown recovery in above mentioned parameters to a great extent. Morphometric calculations of livers and kidneys are given in [Table 1](#).

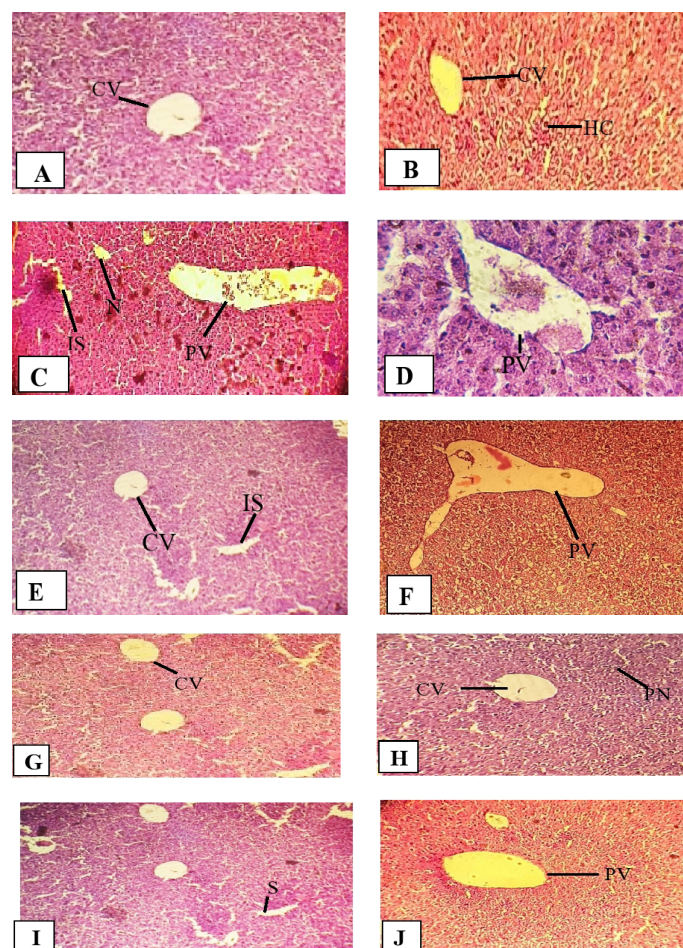
#### Biochemical analysis of serum

Blood serum analysis of BP treated group has shown significant differences in comparison to control and antidote group. LFT and RFT are specified indicators for the hepatic and renal functions. Levels of ALT, AST,

ALP and bilirubin were raised whereas total protein concentration was lowered in BP treated group. Moreover, urea and creatinine levels were also high in BP treated group as compared to control ([Table 1](#)). But in BP+AD group when BP was given along with turmeric, enzyme levels were reversed to some extent but not completely, which showed the limitation of turmeric.

#### Histopathological observations of liver

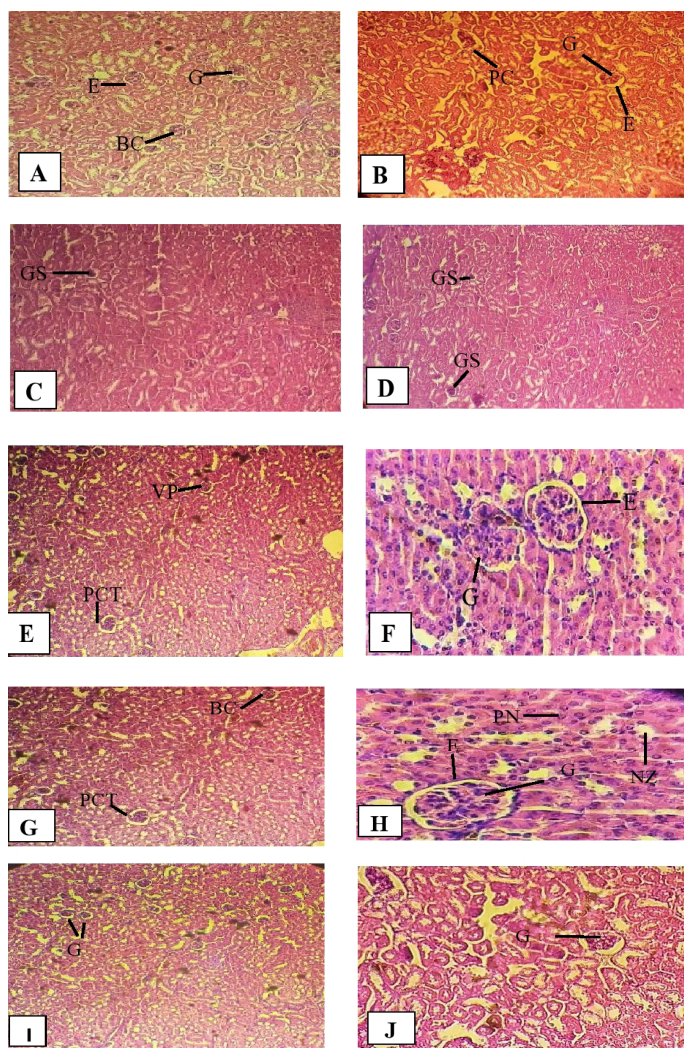
Histopathological analysis of liver in butyl paraben administrated group has shown hepatic portal vein filled with red blood cells and necrotic cells. Group treated with butyl paraben along with turmeric has shown some ameliorative effects as turmeric has reduced the number of red blood cells in central vein. Hepatic tissues obtained from vehicle control and antidote groups were similar with control. Photographs were taken at 100X and 400X ([Figure 1](#)).



**Figure 1: Photomicrographs showing effect of butyl paraben (BP) on histology of liver, normal histopathological sections were seen in control group (A, B). Butyl paraben group (C, D) indicates increase sinusoidal spaces, portal hypertension (PV), and Necrosis (N). BP+ AD group (E, F) shows mild degeneration. VC group mice show few pyknotic nuclei (PN). Antidote (AD) group sections (I, J) were normal like control. Hematoxylin and eosin were stained sections (10X and 40 X).**

*Histopathological outcomes of kidney*

Histology of kidney in control group exhibited regular epithelial cell lining, glomerulus, bowman capsule and proximal convoluted tubules. Whereas renal hemorrhages were seen along with disruption of nuclei, unhealthy epithelium and broad bowman's space in BP administered group. Antidote  $\pm$  dose group had shown reduced renal lesions and normal glomerular morphology. Animals of vehicle and antidote groups showed no damaging effects and were similar to control group. Photographs were taken at 100X and 400X (Figure 2).



**Figure 2: Photomicrographs showing effect of butyl paraben (BP) in kidney., no histopathologic changes were seen among control group (A, B). Butyl paraben sections (C, D) indicate glomerulosclerosis. Dose + antidote group section (E, F) shows abnormal vascular pole (VP), mild degeneration of epithelial cells, and pyknotic nuclei (PN), necrosis (N). Antidote group (I, J) shows no obvious histopathological changes. Hematoxylin and eosin were stained sections (10X and 40 X).**

Contemporary age of industry is rich with many chemicals and compounds that are harmful to human beings. Their ceaseless use in certain commercial and personal products enhances their concentration in both biotic and abiotic environment (Dellafora *et al.*, 2017). Butyl paraben is an environmental toxicant used in food products, cosmetics and pharmaceutical industry mainly as preservative.

In present study, weight of liver and kidney reduced when exposed with butyl paraben at sub chronic level. There was difference in organs weights as compared to control by using only corn oil. Our results are in accordance with (Nowak *et al.*, 2018) who reported peanut oil and corn oil as potent factors for weight loss. Oral administration of butyl paraben indicated effects on liver and kidney because it disturbed the absorption of food and metabolism, resulted a significant decrease in liver and kidney weights. Exposure to butyl paraben reduced the essential currency of cell i.e. ATP production by mitochondria. This lead to weight loss of organs as also reported by Boberg *et al.* (2016); Garcia *et al.* (2017) studies. Morphometric analysis has also shown that length and width of liver and kidney was lowered in BP group as compared to others and use of turmeric has improved these effects to much extent.

Increased concentrations of hepatic enzymes due to action against the harmful effect of butyl paraben were recorded in current study and these results are also reported by Darbre *et al.* (2008). Total protein concentration was reduced whereas bilirubin level in plasma was increased.

In case of kidney, urea and creatinine concentrations in serum of BP group were high as compared to (BP+AD) and control groups and it showed improper glomerular filtration in kidneys. These findings were corroborating with observations of Wahlang *et al.* (2013). As bilirubin levels were high due to the malfunctioning of hepatocytes to remove the metabolites of heme, this also effected the working ability of kidney cells and glomerular filtration rate, so resulted in high levels of urea and creatinine. In normal conditions creatinine is produced as a metabolite of creatine and is processed by kidney and excreted out by urine but when kidneys are not working properly due to any exogenous and endogenous factors, its concentration gets increased (Harvey *et al.*, 2006).

Elevated levels of hepatic enzymes, ALT, AST, ALP and Bilirubin in BP exposed group, as reported in our study was an indication of liver malfunction caused by paraben. This is similar to a lot of studies that state, due to any exogenous or endogenous factor like toxic compounds or viruses, hepatic enzymes balance is disturbed (Abbas *et al.*, 2010). These enzymes are accountable for many metabolic reactions in the hepatic cells. They assist in detoxification of poisonous compounds and also confer antioxidant mechanism.

**Table 1: shows the effect of Butyl paraben on various morphometric and biochemical parameters of liver and kidney in female mice.**

Parameter	Dose group <sup>A</sup>				
	Control	BP	BP + AD	VC	AD
<b>Organ weight (mg ± SEM)</b>					
Liver	1549.0±11.27 <sup>c</sup>	1092.2±21.83 <sup>b</sup>	1343.00±73.12 <sup>bc</sup>	966.00±63.64 <sup>a</sup>	1445.40±33.10 <sup>c</sup>
Kidney	153.33±2.47 <sup>c</sup>	112.16±4.79 <sup>a</sup>	137.00±5.97 <sup>b</sup>	123.33±5.59 <sup>a</sup>	142.67±3.48 <sup>bc</sup>
<b>Organ length (mm± SEM)</b>					
Liver	17.23±0.23 <sup>b</sup>	12.80±0.71 <sup>a</sup>	17.23±0.56 <sup>b</sup>	11.26±0.45 <sup>a</sup>	17.58±1.12 <sup>b</sup>
Kidney	11.44±0.59 <sup>b</sup>	5.48±0.20 <sup>a</sup>	10.19±0.34 <sup>b</sup>	9.84±0.54 <sup>b</sup>	10.21±0.23 <sup>b</sup>
<b>Organ width (mm± SEM)</b>					
Liver	13.35±0.34 <sup>bc</sup>	9.55±0.37 <sup>a</sup>	12.65±0.32 <sup>b</sup>	12.04±0.59 <sup>b</sup>	10.83±0.39 <sup>a</sup>
Kidney	4.35±0.07 <sup>b</sup>	3.46±0.07 <sup>a</sup>	4.17±0.10 <sup>ab</sup>	4.24±0.04 <sup>b</sup>	4.32±0.03 <sup>b</sup>
<b>Liver function test</b>					
Bilirubin (mg/dl)	0.71±0.07 <sup>b</sup>	2.26±0.11 <sup>c</sup>	1.27±0.02 <sup>b</sup>	0.70±0.01 <sup>a</sup>	0.64±0.04 <sup>a</sup>
ALT (U/L)	44.00±3.70 <sup>a</sup>	205.80±9.11 <sup>c</sup>	150.20±8.34 <sup>b</sup>	43.00±3.87 <sup>a</sup>	39.80±2.39 <sup>a</sup>
AST (U/L)	54.80±6.21 <sup>a</sup>	198.50±7.68 <sup>c</sup>	148.40±10.59 <sup>b</sup>	54.00±4.75 <sup>a</sup>	59.44±2.78 <sup>a</sup>
ALP (U/L)	202.70±8.41 <sup>bc</sup>	387.208±8.92 <sup>d</sup>	289.50±18.86 <sup>cd</sup>	246.73±11.33 <sup>c</sup>	180.00±10.79 <sup>a</sup>
Total Protein (g/dl)	7.21±0.36 <sup>bc</sup>	4.13±0.46 <sup>a</sup>	6.51±0.26 <sup>b</sup>	7.00±0.36 <sup>b</sup>	8.01±0.14 <sup>c</sup>
<b>Renal function test</b>					
Urea (mg/dl)	25.90±2.16 <sup>a</sup>	62.60±2.31 <sup>c</sup>	42.70±2.61 <sup>a</sup>	25.09±1.54 <sup>a</sup>	22.56±1.42 <sup>a</sup>
Creatinine (mg/dl)	0.62±0.07 <sup>a</sup>	1.90±0.10 <sup>c</sup>	0.94±0.06 <sup>a</sup>	0.65±0.09 <sup>a</sup>	0.65±0.72 <sup>a</sup>

Δ: For explanation see materials and methods; Values having different superscripts are significantly different from each other at  $p \leq 0.05$ , while non-significant results are represented with same superscripts.

Histopathological finding of this study revealed necrosis and apoptosis in hepatic cells in BP treated group. Hepatic portal vein was also damaged and karyomegaly was seen recurrently and similar effects of BP were shown in study by Martin et al. (2010). On the other side when BP was co administered with turmeric, regenerative or protective potential of turmeric was obvious. Another study also prove the positive impact of turmeric on liver. According to that study damaged epithelial layer was refined to great extent by the active antioxidant effects of Turmeric (Shah et al., 2012).

Malfunctioning of renal cells was also indicated by disrupted and changed epithelial borders of glomerular cells. Debris are seen in peripheral and distal tubules along with necrotic and disruptive cells in glomerulus and bowman's space and showed alike results to the findings of Verma et al. (2007). In BP and antidote group, glomerular filtration was improved because renal cells showed recovery from toxic effects of BP and necrosis and apoptosis of cells was also decreased.

Hence findings of various parameters were synchronized giving valid proof about hepatic and renal toxicity of butyl paraben in above mentioned conditions and efficacy of turmeric as a hepatoprotective and nephroprotective agent.

#### Conflict of interests

The authors declare there is no conflict of interest.

#### References

- Abbas, S., Greige-Gerges, H., Karam, N., Piet, M.H., Netter, P., and Magdalou, J., 2010. Metabolism of parabens (4-hydroxybenzoic acid esters) by hepatic esterases and UDP-glucuronosyltransferases in man. *Drug Metab. Pharmacokinet.*, **25**: 568-577. <https://doi.org/10.2133/dmpk.DMPK-10-RG-013>
- Ahmida, M.H., 2012. Protective role of curcumin in nephrotoxic oxidative damage induced by vancomycin in rats. *Exp. Toxicol. Pathol.*, **64**: 149-153. <https://doi.org/10.1016/j.etp.2010.07.010>
- Alam, M.S., and Kurohmaru, M., 2014. Disruption of Sertoli cell vimentin filaments in prepubertal rats: an acute effect of butylparaben *in vivo* and *in vitro*. *Acta Histochem.*, **116**: 682-687. <https://doi.org/10.1016/j.acthis.2013.12.006>
- Boberg, J., Axelstad, M., Svingen, T., Mandrup, K., Christiansen, S., Vinggaard, A.M., and Hass, U., 2016. Multiple endocrine disrupting effects in rats perinatally exposed to butylparaben. *Toxicol. Sci.*, **152**: 244-256. <https://doi.org/10.1093/toxsci/kfw079>
- Boberg, J., Taxvig, C., Christiansen, S., and Hass, U., 2010. Possible endocrine disrupting effects of parabens

- and their metabolites. *Reprod. Toxicol.*, **30**: 301-312. <https://doi.org/10.1016/j.reprotox.2010.03.011>
- Cekmen, M., Ilbey, Y.O., Ozbek, E., Simsek, A., Somay, A., and Ersoz, C., 2009. Curcumin prevents oxidative renal damage induced by acetaminophen in rats. *Food Chem. Toxicol.*, **47**: 1480-1484. <https://doi.org/10.1016/j.fct.2009.03.034>
- Darbre, P.D., and Harvey, P.W., 2008. Paraben esters: review of recent studies of endocrine toxicity, absorption, esterase and human exposure, and discussion of potential human health risks. *J. Appl. Toxicol.*, **28**: 561-578. <https://doi.org/10.1002/jat.1358>
- Dellaflora, L., and Dall'asta, C., 2017. Forthcoming challenges in mycotoxins toxicology research for safer food—a need for multi-omics approach. *Toxins*, **9**: 18. <https://doi.org/10.3390/toxins9010018>
- El-Mahalaway, A.M., 2015. Protective effect of curcumin against experimentally induced aflatoxicosis on the renal cortex of adult male albino rats: a histological and immunohistochemical study. *Int. J. Clin. Exp. Pathol.*, **8**: 6019.
- Embuscado, M.E., 2015. Spices and herbs: Natural sources of antioxidants—a mini review. *J. Funct. Foods*, **18**: 811-819. <https://doi.org/10.1016/j.jff.2015.03.005>
- Fransway, A.F., Fransway, P.J., Belsito, D.V., and Yiannias, J.A., 2019. Paraben toxicology. *Dermatitis*, **30**: 32-45. <https://doi.org/10.1097/DER.0000000000000428>
- Garcia, T., Schreiber, E., Kumar, V., Prasad, R., Sirvent, J.J., Domingo, J.L., and Gómez, M., 2017. Effects on the reproductive system of young male rats of subcutaneous exposure to n-butylparaben. *Food Chem. Toxicol.*, **106**: 47-57. <https://doi.org/10.1016/j.fct.2017.05.031>
- Giulivo, M., De Alda, M.L., Capri, E., and Barceló, D., 2016. Human exposure to endocrine disrupting compounds: Their role in reproductive systems, metabolic syndrome and breast cancer. *Rev. Environ. Res.*, **151**: 251-264. <https://doi.org/10.1016/j.envres.2016.07.011>
- Harvey, P.W., and Everett, D.J., 2006. Regulation of endocrine-disrupting chemicals: critical overview and deficiencies in toxicology and risk assessment for human health. *Best Pract. Res. Clin. Endocrinol. Metab.*, **20**: 145-165. <https://doi.org/10.1016/j.beem.2005.09.008>
- Hewlings, S.J., and Kalman, D.S., 2017. Curcumin: a review of its' effects on human health. *Foods*, **6**: 92. <https://doi.org/10.3390/foods6100092>
- Kulka, M., 2016. A review of paraoxonase 1 properties and diagnostic applications. *Polish J. Vet. Sci.*, **19**: 225-232. <https://doi.org/10.1515/pjvs-2016-0028>
- Martín, J.M.P., Peropadre, A., Herrero, Ó., Freire, P.F., Labrador, V., and Hazen, M.J., 2010. Oxidative DNA damage contributes to the toxic activity of propylparaben in mammalian cells. *Mutat. Res. Genet. Toxicol. Environ. Mutagenesis*, **702**: 86-91. <https://doi.org/10.1016/j.mrgentox.2010.07.012>
- Nabavi, S.F., Moghaddam, A.H., Eslami, S., and Nabavi, S.M., 2012. Protective effects of curcumin against sodium fluoride-induced toxicity in rat kidneys. *Biol. Trace Elem. Res.*, **145**: 369-374. <https://doi.org/10.1007/s12011-011-9194-7>
- Nowak, K., Ratajczak-Wrona, W., Górska, M., and Jabłońska, E., 2018. Parabens and their effects on the endocrine system. *Mol. Cell. Endocrinol.*, **474**: 238-251. <https://doi.org/10.1016/j.mce.2018.03.014>
- Oishi, S., 2001. Effects of butylparaben on the male reproductive system in rats. *Toxicol. Ind. Health*, **17**: 31-39. <https://doi.org/10.1191/0748233701th0930a>
- Shah, K.O.M.A.L., and Verma, R.J., 2012. Protection against butyl p-hydroxybenzoic acid induced oxidative stress by *Ocimum sanctum* extract in mice liver. *Acta Pol. Pharm.*, **69**: 865-870.
- Shi, W., Zhang, D., Wang, L., Sreeharsha, N., and Ning, Y., 2019. Curcumin synergistically potentiates the protective effect of sitagliptin against chronic deltamethrin nephrotoxicity in rats: Impact on pro-inflammatory cytokines and Nrf2/Ho-1 pathway. *J. Biochem. Mol. Toxicol.*, e22386. <https://doi.org/10.1002/jbt.22386>
- Verma, R. J., and Asnani, V., 2007. Ginger extract ameliorates paraben induced biochemical changes in liver and kidney of mice. *Acta Pol. Pharm.*, **64**: 217-220.
- Wahlang, B., Beier, J.I., Clair, H.B., Bellis-Jones, H.J., Falkner, K.C., McClain, C.J., and Cave, M.C., 2013. Toxicant-associated steatohepatitis. *Toxicol. Pathol.*, **41**: 343-360. <https://doi.org/10.1177/0192623312468517>
- Watkins, D.J., Ferguson, K.K., Del Toro, L.V.A., Alshawabkeh, A.N., Cordero, J.F., and MEEKER, J.D., 2015. Associations between urinary phenol and paraben concentrations and markers of oxidative stress and inflammation among pregnant women in Puerto Rico. *Int. J. Hyg. Environ. Health*, **218**: 212-219. <https://doi.org/10.1016/j.ijheh.2014.11.001>
- Zhang, Y., Keefe, A.D., and Dumelin, C., 2017. U.S. Patent Application No. 15/504, 223.