



Review Article

Xylazine and Lidocaine: Uses of High Epidural Anesthesia in the Domesticated Small Animals

Muhammad Yousif Jakhrai¹, Ahmed Nawaz Tunio², Ali Mujtaba Shah^{1*}, Tarique Ahmed Khokhar¹, Muhammad Mohsen Rahimoon¹

¹Shabeed Benazir Bhutto University of Veterinary and Animal Sciences, Sakrand, Sindh, Pakistan

²Department of Surgery and Obstetrics, Faculty of animal husbandry and veterinary science, Sindh Agriculture University, Tandojam, Sindh, Pakistan

Article History

Received: December 28, 2020

Revised: January 26, 2021

Accepted: March 07, 2021

Published: June 09, 2021

Authors' Contributions

MYJ wrote the manuscript and collected material. ANT revised the manuscript. AMS, TAK and MMR Revised the manuscript and collected material.

Keywords

High epidural, Xylazine, Lidocaine, Domesticated small animals

Abstract | The current study was conducted to investigate the recent literature concerning latest achievements in the high epidural anesthetic technique and high epidural anesthetic drugs injected to induce epidural analgesia in small ruminants like caprine and ovine. The information was obtained from published papers of last twenty years via research gateways such as; PubMed, Scopus and Google Scholar. Small ruminant anesthesia, local anesthesia in ruminants and high epidural analgesia in sheep and goats were key points for this review. However, these research papers were included in this study, were published between from 1999 to 2017. The bibliographies of these references were also used for reviewing the High epidural anesthesia in small animals. However, a total of 29 articles were reviewed for this study. The scope of lumbosacral epidural analgesia and also its clinical application was studied. The most commonly anesthetic agents injected to produce high epidural analgesia in ovine and caprine species were 2% lidocaine and xylazine were included in this study. This study showed that administration of xylazine in high epidural anesthesia produce a significant analgesic and sedative effect for laparotomy (peritoneal) surgical interventions in ovine and caprine species as compared to lidocaine.

Novelty Statement | This comprehensive review will be very helpful to reduce anesthetic risk by using high epidural analgesia in small ruminants for hindquarter surgical procedures like hysterotomy, celiotomy, rumenotomy, repair of prolapse (vagina, rectum and uterus) hernia and other abdominal affections.

To cite this article: Jakhrai M.Y., Tunio, A.N., Shah, A.M., Khokhar, T.A. and Rahimoon, M.M., 2021. Xylazine and lidocaine: Uses of high epidural anesthesia in the domesticated small animals. *Punjab Univ. J. Zool.*, 36(1): 31-36. <https://dx.doi.org/10.17582/journal.pujz/2021.36.1.31.36>

Introduction

Anesthesia is defined as reversible loss of pain, unconsciousness, amnesia, muscle relaxation and immobility with low side effects Ukwueze *et al.* (2014). However, anesthesia may be general or local, while general

surgical anesthesia is sub divided into two types such as; (intra-muscular and intra-venous) and inhalant Biswas *et al.* (2017). Furthermore, local anesthesia is used through infiltration, ring block, field block and epidural administration technique with or without other anesthetic agents like; sedatives, tranquilizing agents, pain killers and muscle relaxants in order reduce the anesthetic dose and overcome the resistance of the animals during examination, maintaining depth of anesthesia and increase safety Omar *et al.* (2017).

Corresponding Author: Ali Mujtaba Shah

mujtaba43@gmail.com; alimujtabashah@sbbuvas.edu.pk

Epidural anaesthesia is defined as injection of anaesthetic agents into epidural space [Steagall *et al.* \(2017\)](#), because it provides good analgesia in flank, perineal and pelvic region [DeRossi *et al.* \(2017\)](#). Whereas, epidural anesthesia is the sub-class of local anesthesia. The epidural and extra dural refers to the space outside the dura mater. When sedative and analgesics are directly administered into the epidural space that is called epidural analgesia ([Natalini, 2010](#)).

However, it is administered by two methods, high and low epidural anesthesia i.e. Lumbosacral and Sacrococcygeal epidural anaesthesia [Figure 1 Silva *et al.* \(2017\)](#). Furthermore, high epidural anesthesia is administered in between inter-vertebral space of last lumbar and first sacral vertebrae. This type of anesthesia is used for various surgical procedures of hindquarter such as; hysterotomy, celiotomy, rumenotomy, repair of prolapse (vagina, rectum and uterus) hernia and other abdominal affections ([Skarda and Tranquilli, 2007](#)). Furthermore, the most common site for administration of epidural injection in small ruminants is space between last lumbar and first sacral vertebrae and this space is just above the first layer of meninges (dura mater) and just below the outer layer of vertebrae (periosteum), this area is ideal for injection of anesthetic drugs because this area is very much vascular and very sensitive due to presence of nerves of the cauda equine and in some species, the remaining layers of the spinal cord (the meninges i.e; pia and arachnoid mater) may also be found there [Hall *et al.* \(2001\)](#). On other hand, the lumbosacral space is difficult to locate in those animals which are suffering from neurological diseases, spinal cord trauma, low-dose heparin therapy and anatomical changes including trauma of the pelvic area and obesity ([Jones, 2001](#)). Whereas, low epidural anesthesia is administered in between last sacral and first coccygeal vertebral space or in between first and second coccygeal vertebrae [Steagall *et al.* \(2017\)](#). This technique is easy to used and performed surgery on standing animals in various surgical procedures of tail, vagina, vulva, anus, rectum, caudal prepuce, scrotum and urethra [Molaei *et al.* \(2010\)](#).

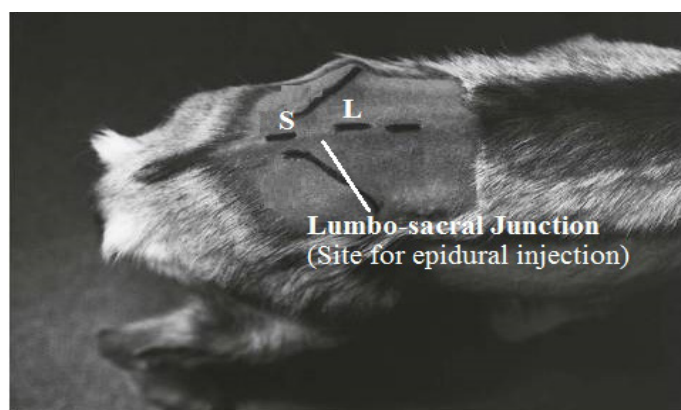


Figure 1: Lumbo-sacral epidural space in goats ([Skarda and Tranquilli, 2007](#)).

Table 1: Epidural administration dose rate of xylazine and lidocaine in different animals.

S. No.	Name of animal	Xylazine	Lidocaine
1	Dog	0.75mg (Fani <i>et al.</i>, 2008)	6--3 mg (Garcia, 2018)
2	Cattle	0.05mg (Grubb <i>et al.</i>, 2002)	0.22 mg (Ismail <i>et al.</i>, 2018)
3	Buffalo	0.05mg (Singh <i>et al.</i>, 2005)	2.0mg (Singh <i>et al.</i>, 2005)
4	Goat	0.1mg (DeRossi <i>et al.</i>, 2005)	2.5mg (DeRossi <i>et al.</i>, 2005)
5	Rabbit	3mg (Marjani <i>et al.</i>, 2014)	4mg (Marjani <i>et al.</i>, 2014)

In veterinary practice, usually epidural anesthesia is used to control the pain during surgery ([Ismail, 2016](#)). In the intra-operative time pain, inhalation and surgical pain management requirements are reduced by injection of epidural analgesia ([Steagall *et al.*, 2017](#)). Epidural anesthesia inhibit the central sensitization and alter the afferent signals to the dorsal horn and serum concentration of cortisol and norepinephrine also decreases up to 48 hours after injection which suppress the stress.

However, spinal needle (22 Gauge and 1-inch long) is inserted through skin, subcutaneous fascia, and the ligamentum flavum, which forms the dorsal wall of the epidural space in order to access the lumbosacral intervertebral space ([Skarda and Tranquilli, 2007](#)). When the local anesthetics are injected into lumbosacral epidural space, they block the intra-dural spinal nerve roots and the peripheral layer of the spinal cord in order to produce complete analgesia to the posterior half of the animal body without any life-threatening risk [Troncy *et al.* \(2002\)](#). Whereas, the lumbosacral junction is the site of lumbosacral epidural anaesthesia in small ruminants [Steagall *et al.* \(2017\)](#). This junction is easily palpated in thin animals than fatty animals because in fatty animals it is necessary to draw the landmark of lumbosacral space in small ruminants with standing or in lateral recumbency position [Hall *et al.* \(2001\)](#). The dura mater is above the arachnoid mater and the pia mater. While, cerebrospinal fluid is present in subarachnoid space. Hence, intrathecal or pinal injection is inserted into the subarachnoid space and it is not commonly used in small animals [Steagall *et al.* \(2017\)](#).

Scope of epidural anaesthesia

Generally epidural anaesthetic technique is frequently used in goats and sheep to perform hindquarter operations ([Skarda and Tranquilli, 2007](#)). This procedure is also used for analgesia in animals. In addition, the hysterotomy, bone operations and other caudle laparotomy procedures are commonly performed through this analgesia [Hewitt](#)

et al. (2007). Because of regurgitation problems during general anesthesia in ruminants, the epidural anesthesia is performed (Ismail, 2016). Moreover, epidural anaesthesia is also beneficial for surgery due to its uniform desensitization of all the laparotomical layers including skin, muscles and peritoneal layer and also helpful for embryo transfer in animals Khajuria *et al.* (2014).

However, xylazine and lidocaine are being used epidurally in many animals like equines, bovines, ovines, caprines and camels Molaei *et al.* (2010). But, alpha₂ agonist (Xylazine) is frequently injected into the epidural space of the ruminants, because it enhances the analgesic effect and decline in motor function of rare quarter Singh *et al.* (2005). Whereas, in donkeys and horses prolonged analgesia of caudal region is achieved by injecting alpha₂ agonist drug into epidural space Mpanduji *et al.* (1999). While, the scrotal herniorrhaphy in pig is performed under epidural anaesthesia Ekstrand *et al.* (2015). The ropivacaine do not produce any adverse effect of overdose in rabbit epidural anesthesia (Derossi *et al.*, 2005). The epidural anesthesia decreases the side-effects and increase the safety of animal Singh *et al.* (2005).

Practical use of epidural anaesthesia in ruminants

In veterinary practice for treatment of different surgical and obstetrical interventions of pelvic region, reproductive, renal system and hind quarters of domestic animals epidural anaesthesia is commonly used Dehkordi *et al.* (2012). While, general anesthesia may produce undesirable results in ruminants Habibian *et al.* (2011), because during general anesthesia animal may take food particle, saliva or other material into the respiratory tract due to its regurgitating ability Azari *et al.* (2014).

However, in ruminants epidural anesthesia is comparatively uncomplicated method for diagnostic procedures and regional surgery Khajuria *et al.* (2014). Such as, hysterotomy, celiotomy, rumenotomy, repair of prolapse (vagina, rectum and uterus) hernia and other abdominal affections and surgery of the prepuce, penis or hind limbs (Skarda and Tranquilli, 2007). This type of anaesthesia is comparatively safe. Therefore, it is used frequently prior to diagnostic, obstetrical and surgical procedures in small ruminants Khajuria *et al.* (2014). These drugs are cheap, easily available and having good analgesia Hall *et al.* (2001). Dissimilar to local infiltration, epidural anaesthesia desensitize all the layers of abdomen including the peritoneum and also increase intra-abdominal space in laproscopy procedures for easy manipulations Khajuria *et al.* (2014).

Dystocia and prolapse of uterus are significant problems and have been encountered in small ruminants Bigham *et al.* (2009). Whereas, both conditions could be solved by surgical manipulation (Ismail, 2016). Therefore,

anesthesia play an important role to control the animal by using safe anesthetic agents. Meanwhile, ruminants are at high risk for anesthesia, due to number of anesthetic complication have been observed during surgery such as tympany, regurgitation and muscular structure damage Habibian *et al.* (2011). Therefore, alternate method such as; epidural anesthesia is preferred in small ruminants to perform many different surgical procedures. Though, dystocia, prolapse of rectum, prolapse of uterus and posterior udder surgery in female animal, problems would be easier to solve when using epidural anesthesia. But epidural anesthesia is also best for castration in buck through surgical method (Ismail, 2016). However, epidural anaesthesia is used in ruminants for the treatment of other obstetrical and surgical interventions of hind limb area such as; surgery of anus, vulva, perineum, caudal udder, and scrotum (Ismail, 2016).

Commonly used drugs in epidural anesthesia

The bupivacane, lidocaine, tremadol and xylazine are more frequently used drugs for induction of high epidural anesthesia in ruminants (Ismail, 2016).

Xylazine HCL

The use of alpha₂ adrenergic agonists in domestic animals has become famous for good analgesia Kalhoro (2006). However, it is more frequently used in veterinary science by noxious stimuli produces analgesia by inhibiting the spinal substance release and nociceptive neuron firing produced by noxious stimuli and produces analgesia and also stimulates the alpha₂ adrenergic receptors of the spinal cord for sedation. (Ismail, 2016). However, it causes the sedation, hypotension, bradycardia, and respiratory depression in goats and horses Molaei *et al.* (2010); Kalhoro (2006). These drugs are more effective for epidural or subarachnoid analgesia in domestic animals (Ismail, 2016). The alpha₂ agonists are superior to anaesthetic agents because it produces the duration of action and reduced disruption of the motor function of the hind limbs in cattle Molaei *et al.* (2010).

Xylazine is used for epidural anesthesia in sheep, goat, cows, buffalos, horses and camels Singh *et al.* (2005). While, epidurally administered alpha₂ agonists produces analgesia by activating presynaptic alpha₂ adrenergic receptors located on primary afferent fibres terminating in the dorsal horn of the spinal cord, as well as postsynaptic alpha₂ receptors located on wide dynamic range projection neurons in the dorsal horn Schug *et al.* (2006).

While, Xylazine is used at 0.025mg/kg to 0.5 mg/kg body weight in ruminants (Ismail, 2016) whereas, the dose rate of xylazine is different in different animals as mentioned in Table 1. When the lowest possible dose of xylazine and lidocaine is used in epidural space, the onset of epidural anesthesia is commonly occurs within 10 minutes and

duration of sedation remains for 3-4 hours. Time may be increased up to 5 minutes and 6 hours, when xylazine given at dose rate of 0.03-0.05 mg/kg body weight and also combined with lidocaine (Ismail, 2016). Meanwhile, the onset of action of xylazine is delayed, but duration of action is longer by epidural anaesthesia in many animal species (Ismail, 2016).

Xylazine induces a state of drowsiness with a high dose-dependent degree of analgesia, generalized muscle relaxation of central origin and cardiopulmonary depression. Xylazine can even have local anaesthetic effects Derossi *et al.* (2003). Xylazine may produce sedation with a high dose-dependent degree of analgesia, generalized muscle relaxation of central origin, cardiovascular and respiratory depression when administered parentally into the domesticated animals Molaei *et al.* (2010). While, it produces analgesia of the perineal region without the adverse effects such as hypotension, neuro-toxicosis, severe ataxia of other locally administered anesthetics, when used epidurally in rams, ponies, cattle, horses and llamas. While, cardio-pulmonary effect of xylazine is very less when epidural route is used as compare to intramuscular route DeRossi *et al.* (2003).

Presently, alpha₂ agonists such as, xylazine is frequently administered into the epidural space in many domestic animals but contraindicated in cardiovascular patients because it may cause bradycardia, hypotension and vomiting Molaei *et al.* (2010).

Lidocaine HCL

Lidocaine hydrochloride 2% is the local analgesic drug composed of amino-amide class, which is most commonly used for epidural analgesia in cattle, camel, buffalo, sheep and goat (Ismail, 2016). This analgesic alters the fast voltage-gated by blocking signal conduction in sodium channel of the neuronal cell membrane (Skarda and Tranquilli, 2007). In ruminants lidocaine hydrochloride 2-5 mg/ kg bodyweight is administered epidurally whereas, the epidural dose rate of lidocaine is different in different animals as mentioned in Table 1. However, it is used with or without other anesthetic agents to produce good analgesia at tail, anus and perineum in ruminants (Ismail, 2016). The time of analgesia may be prolonged when lidocaine is mixed with epinephrine (Rostami and Vesal, 2012).

The time of onset of analgesia with lidocaine as epidural anaesthesia is 3-5 minutes after administration and effect remains for 2.5 hours and depending on the dose. Usually 2-8 mg/kg body weight is recommended. While, lidocaine produces rapid onset but its effect lasts earlier than xylazine in horses, ponies and cattle (Ismail, 2016). Furthermore, analgesia is produced by lidocaine is relatively short duration and incremental dose will allow

completion of the surgical procedure Atiba *et al.* (2015). In addition, local anaesthetic agents indiscriminately block motor, sensory and sympathetic fibers causing ataxia, hind limb weakness and occasionally recumbency (Ismail, 2016). Lidocaine blocks the sensory, motor and sympathetic nerve by axonal depression of nerves Derossi *et al.* (2005). The drugs with greater duration of action injected in epidural space for those surgical procedures which requires long duration analgesia Molaei *et al.* (2010). While, sympathetic blockade due to epidural injection of local anaesthetics may results in the vasodilatation. However, vasodilatation reduces the period of anaesthesia and produces the hypotension Derossi *et al.* (2005).

General anesthesia may produce undesirable results in ruminants Habibian *et al.* (2011), because during general anesthesia animal may take food particle, saliva or other material into the respiratory tract due to its regurgitating ability Azari *et al.* (2014). However, in ruminants epidural anesthesia is comparatively uncomplicated method for diagnostic procedures and regional surgeries Khajuria *et al.* (2014). Such as, like hysterotomy, celiotomy, rumenotomy, repair of prolapse (vagina, rectum and uterus) hernia and other abdominal affections and surgery of the prepuce, penis or hind limbs (Skarda and Tranquilli, 2007).

Conclusions and Recommendations

The high epidural anesthesia is safe as compared to general anesthesia in ruminants because during general anesthesia animal may take food particle, saliva or other material into the respiratory tract due to its regurgitating ability. The xylazine alone produced good sedative effects as compared to lidocaine alone when administered in lumbosacral space. Furthermore, xylazine alone produced slow onset of analgesia but it produces more sedative and analgesic effects as compared to lidocaine alone. This agent may be used in clinical practice for complete and safe regional sedative and analgesic effects for obstetrical and surgical interventions. Finally, xylazine is recommended for epidural analgesia in small ruminants. However, further studies require investigating the optimum dose for particular obstetrical and surgical intervention.

Conflict of interest

The authors have declared no conflict of interest.

References

- Atiba, A., Ghazy, A., Gomaa, N., Kamal, T. and Shukry, M., 2015. Evaluation of analgesic effect of caudal epidural tramadol, tramadol-lidocaine, and lidocaine in water buffalo calves (*Bubalus bubalis*). *Vet. Med. Int.*, Article ID: 575101, pp. 6. <https://doi.org/10.1155/2015/575101>

- Azari, O., Molaei, M., M. and Roshani, H., 2014. Caudal epidural analgesia using lidocaine alone and in combination with tramadol in dromedary camels. *Iran. J. Vet. Surg.*, **9**: 27-32. <https://doi.org/10.4102/jsava.v85i1.1002>
- Bigham, S.A., Shafiei, Z. and Dehghani, N.S., 2009. Comparison of epidural anesthesia with lidocaine-distilled water and lidocaine-magnesium sulfate mixture in goat. *Vet. Arhiv.*, **79**: 11-17.
- Biswas, D.S., Hasan, M., Mallick, S., Juyena, N.S., Shoriotullah, M. and Alam, M.R., 2017. Clinical and haematological changes upon administration of Xylazine-Ketamine and Xylazine-Thiopentone anaesthetic combinations in ewes. *Bangladesh Vet.*, **34**: 9-19. <https://doi.org/10.3329/bvet.v34i1.38708>
- Dehkordi, S.H., Sadegh, A.B. and Gerami, R., 2012. Evaluation of anti-nociceptive effect of epidural tramadol, tramadol-lidocaine and lidocaine in goats. *Vet. Anesth. Analg.*, **39**: 106-110. <https://doi.org/10.1111/j.1467-2995.2011.00655.x>
- Derossi, R., Beretta, M.P., and Junqueira, A.L., 2005. Analgesic and systemic effects of xylazine, lidocaine and their combination after subarachnoid administration in goats. *J. South Afr. Vet. Assoc.*, **76**: 79-84. <https://doi.org/10.4102/jsava.v76i2.402>
- Derossi, R., Lopes, A., Juqueira, A.L. and Paixão, M.B., 2003. Analgesic and systemic effects of ketamine, xylazine and lidocaine after subarachnoid administration in goats. *Am. J. Vet. Res.*, **6**: 51-56. <https://doi.org/10.2460/ajvr.2003.64.51>
- Derossi, R., Pagliosa, R.C., De-Carvalho, A.Q., Macedo, G.G. and Hermeto, L.C., 2017. Fentanyl and methadone used as adjuncts to bupivacaine for lumbosacral epidural analgesia in sheep. *Vet. Rec.*, **180**: 96. <https://doi.org/10.1136/vr.103860>
- Ekstrand, C., Sterning, M., Bohman, L. and Edner, A., 2015. Lumbo-sacral epidural anaesthesia as a complement to dissociative anaesthesia during scrotal herniorrhaphy of livestock pigs in the field. *Acta Vet. Scand.*, **57**: 33. <https://doi.org/10.1186/s13028-015-0124-0>
- Fani, F.A., Mehesare, S.P., Pawshe, D.B., Khan, K.M. and Jadhav, D., 2008. Haematological and biochemical changes during epidural xylazine hydrochloride anaesthesia in dogs. *Vet. World*, **1**: 175-177.
- Garcia-Pereira, F., 2018. Epidural anesthesia and analgesia in small animal practice: An update. *Vet. J.*, **242**: 24-32. <https://doi.org/10.1016/j.tvjl.2018.09.007>
- Grubb, T.L., Riebold, T.W., Crisman, R.O. and Lamb, L.D., 2002. Comparison of lidocaine, xylazine, and lidocaine-xylazine for caudal epidural analgesia in cattle. *Vet. Anesth. Analg.*, **29**: 64-68. <https://doi.org/10.1046/j.1467-2995.2001.00068.x>
- Habibian, S., Bigham, A.S. and Aali, E., 2011. Comparison of lidocaine, tramadol, and lidocaine-tramadol for epidural analgesia in lambs. *Res. Vet. Sci.*, **91**: 434-438. <https://doi.org/10.1016/j.rvsc.2010.09.023>
- Hall, L.W. and Clarke, K.W. and Trim, C.M., 2001. Anaesthesia of sheep, goats and other herbivores. *Vet. Anaesth.*, **10**: 341-357. <https://doi.org/10.1016/B978-070202035-3.50014-0>
- Hewitt, S.A., Brisson, B.A., Sinclair, M.D. and Sears, W.C., 2007. Comparison of cardiopulmonary responses during sedation with epidural and local anesthesia for laparoscopic-assisted jejunostomy feeding tube placement with cardiopulmonary responses during general anesthesia for laparoscopic-assisted or open surgical jejunostomy feeding tube placement in healthy dogs. *Am. J. Vet. Res.*, **68**: 358-369. <https://doi.org/10.2460/ajvr.68.4.358>
- Ismail, Z.B. 2016. Epidural Analgesia in sheep and goats: A review of recent literature. bulletin of the University of Agricultural Sciences & Veterinary Medicine Cluj-Napoca. *Vet. Med.*, **73**(2): 197-202.
- Ismail, Z.B., Abi-Basha, E., Alzghoul, A., Salah, A. and Al-Zoubi, I., 2018. Epidural co-administration of neostigmine and lidocaine or xylazine enhances systemic sedation but not perineal analgesia in adult dairy cows. *Veterinárni med.*, **63**: 306-312. <https://doi.org/10.17221/25/2018-VETMED>
- Jones, R.S., 2001. Epidural analgesia in the dog and cat. *Vet. J.*, **161**: 123-131. <https://doi.org/10.1053/tvjl.2000.0528>
- Kalhor, A.B., 2006. Sedative effects of acepromazine and xylazine in horses: A comparative study. *Pak. J. Biol. Sci.*, **9**: 72-75. <https://doi.org/10.3923/pjbs.2006.72.75>
- Khajuria, A., Shah, R.A., Khan, F.A., Bhat, M.H., Yaqoob, S.H., Naykoo, N.A. and Ganai, N.A., 2014. Comparison of two doses of ropivacaine hydrochloride for lumbosacral epidural anaesthesia in goats undergoing laparoscopy assisted embryo transfer. *Int. Sch. Res. Not.*, 2014. <https://doi.org/10.1155/2014/937018>
- Marjani, M., Tavakoli, A., and Tavakoli, J., 2014. Comparison the Analgesic Effects of Lidocaine, Xylazine and their Combination Used into the Epidural Space in Rabbits. *Iran. J. Vet. Surg.*, **9**: 17-22.
- Molaei, M.M., Azari, O., Sakhaee, E., Naderi, Z. and Mehdizadeh, S., 2010. Comparison of lidocaine, xylazine, and a combination of lidocaine and xylazine for caudal epidural analgesia in dromedary camels. *Iran. J. Vet. Surg.*, **5**: 51-62.
- Mpanduji, D.G., Mgasa, M.N., Bittegeko, S.B.P. and Batamuji, E.K., 1999. Comparison of xylazine and lidocaine effects for analgesia and cardiopulmonary functions following lumbosacral epidural injection in goats. *J. Vet. Med. A*, **46**(10): 605-611.

- Natalini, C.C., 2010. Spinal anesthetics and analgesics in the horse. *Vet. Clin. Equine Pract.*, **26**: 551-564. <https://doi.org/10.1016/j.cveq.2010.07.005>
- Omar, R.A., Aziz, O.K., Eesa, M.J., and Abed, B.S., 2017. Comparative study for three protocols of general anesthesia in bucks. *Iraqi J. Vet. Med.*, **41**: 15-23. <https://doi.org/10.30539/iraqijvm.v41i2.42>
- Rostami, M. and Vesal, N., 2012. The effects of adding epinephrine or xylazine to lidocaine solution for lumbosacral epidural analgesia in fat-tailed sheep. *J. South Afr. Vet. Assoc.*, **83**: 7-14. <https://doi.org/10.4102/jsava.v83i1.1>
- Schug, S.A., Saunders, D., Kurowski, I. and Paech, M.J., 2006. Neuraxial drug administration. *CNS Drugs*, **20**: 917-933. <https://doi.org/10.2165/00023210-200620110-00005>
- Silva, D.S.P., Fantinato-Neto, P., Silva, A.N.E., Junior, E.H.B. and Carregaro, A.B., 2017. Thoracolumbar epidural anaesthesia with 0.5% bupivacaine with or without methadone in goats. *Irish Vet. J.*, **70**: 15. <https://doi.org/10.1186/s13620-017-0093-x>
- Singh, K., Kinjavdekar, P., Aithal, H.P., Gopinathan, A., Singh, G.R., Singh, T. and Pratap, K., 2005. Clinicophysiological and haematobiochemical effects of epidural ropivacaine in uraemic and healthy caprines. *Indian J. Vet. Surg.*, **32**: 11-15.
- Singh, P., Pratap, K., Kinjavdekar, P., Aithal, H.P. and Singh, G.R., 2005. Effects of xylazine, lignocaine and their combination for lumbar epidural analgesia in water buffalo calves (*Bubalus bubalis*). *J. South Afr. Vet. Assoc.*, **76**: 151-158. <https://doi.org/10.4102/jsava.v76i3.417>
- Skarda, R.T. and Tranquilli, W.J., 2007. Local and regional anesthetic and analgesic techniques: Ruminants and swine. In: (eds. Tranquilli, W.J., Thurmon, J.C. and Grimm, K.A.). *Lumb and Jones Vet. Anesth. Analg.*, 4th edition. Ames (IA): Blackwell, pp. 643-681.
- Steagall, P.V., Simon, B.T., Teixeira Neto, F.J. and Luna, S.P., 2017. An Update on Drugs Used for Lumbosacral Epidural Anesthesia and Analgesia in Dogs. *Front. Vet. Sci.*, **4**: 68. <https://doi.org/10.3389/fvets.2017.00068>
- Troncy, E., Junot, S., Keroack, S., Sammut, V., Pibarot, P., Genevois, J.P. and Cuvelliez, S., 2002. Results of preemptive epidural administration of morphine with or without bupivacaine in dogs and cats undergoing surgery: 265 cases (1997-1999). *J. Am. Vet. Med. Assoc.*, **221**: 666-672. <https://doi.org/10.2460/javma.2002.221.666>
- Ukwueze, C.O., Eze, C.A., and Udegbonam, R.I., 2014. Assessment of common anaesthetic and clinical indices of multimodal therapy of propofol, xylazine and ketamine in total intravenous anaesthesia in West African Dwarf Goat. *J. Vet. Med.*, Volume 2014. Article ID 962560. <https://doi.org/10.1155/2014/962560>