

## **CHEMOTHERAPEUTIC ROLE OF BIS 3-AZOPHENYL-4-HYDROXY-6-METHYL-2H-PYRAN-2-ONE IRON (II) IN CHEMICALLY INDUCED SKIN CANCER IN ALBINO RATS**

SAMINA SHAHID, JAVAID IQBAL AND MUHAMMAD SHARIF MUGHAL

*Institute of Chemistry, University of the Punjab (SS, JI); Department of Zoology, G.C. University, Lahore (MSM), Pakistan*

**Abstract:** The present study was designed to see the effect of bis 3-Azophenyl-4-Hydroxy -6-Methyl-2-H-Pyran-2-one iron (II) (complex) in (DMBA), 7, 12 Dimethylbenz [a] Anthracene followed by 12-O-Tetradecanoyl-phorbol-13-Acetate, (TPA) induced tumours on the skin of albino rats. Eighty albino rats were divided into four groups. Groups A & B were used as control. DMBA was given to group C 100µg/ml as single dose along with @ TPA 10µg/ml in acetone twice a week. In-group D all the chemical carcinogens (DMBA & TPA) were applied locally in the same dose, route and schedule, after the induction of skin cancer, the complex (bis 3-Azophenyl-4-Hydroxy-6-Methyl-2H-Pyran-2-one iron (II) was applied by the same route followed by study of therapeutic role.

**Key words:** 7,12- Dimethylbenz [a] anthracene, 12-O-tetradecanoyl-phorbol-13-acetate, skin cancer, chemical carcinogenesis, therapeutic role,

### **INTRODUCTION**

Cell division or cell proliferation is a physiological process that occurs in almost all tissues under many circumstances. Normally the balance between proliferation and programmed cell death is tightly regulated to ensure the integrity of organs and tissues. Mutations in DNA that lead to cancer disrupt these orderly processes. Leong realized tumor behaved in body different way (Leong and Leong 1989). The uncontrolled and often rapid proliferation of cells can lead to either a benign tumor or a malignant tumor (cancer). Benign tumors do not spread to other parts of the body or

invade other tissues, and they are rarely a threat to life. Malignant tumors can invade other organs, spread to distant locations (metastize) and become life threatening. In 1861, Robert Bentley of King College, London, noted the antitumor properties of an extract of the common May apple (*Podophyllum peltatum*). Scientists soon had the ability to analyze such “natural products” to determine “active ingredients.” Compounds in the plant responsible for the observed therapeutic properties.

Pyrones and their derivatives have been widely acknowledged compounds an account of the fact that they are natural products. J.N. Collie year carried out ground breaking research to prepare triacetic lactone (Siddiq 1982). Pyrones has displayed remarkable utility for antibacterial, antifungal (Rehaman, 2005). The transitional metal complexes with hetrocyclic systems containing nitrogen and sulphur atoms have been studied extensively because of antitumor (Rosenberg *et al.* 1970, Kalsoom *et al.*, 1996, Bhatti *et al.*, 2001, Chohan *et al.*, 2003) activities. It is an established fact that most of the transition metals also posses similar properties (Dollet *et al.*, 1985). Having combined the two, we attained complexes which have much enhanced activity. The study was undertaken with the intention of studying the effects of chemical carcinogens on the skin of rats with initiation-promotion protocol and the use of previously reported complex (Shahid *et al.*, 2005) bis 3-Azophenyl-4-hydroxy-6-methyl-2H-pyran-2-one iron (II) as therapeutic agent.

## MATERIALS AND METHODS

Eighty adult and healthy albino rats were selected for experimental study. They were divided into four groups (twenty each) A, B, C, D. The animals were obtained from veterinary research institute, Lahore. The rats were kept under optimal atmospheric and hygienic conditions. All the four groups kept in separate iron cages fitted with removable gauze lids that had been especially designed for keeping the cages clean. The cages were labeled with their respective identification markings. The animals were allowed and facilitated to acclimatize in the animal house for one week before the experiment was started. Two chemicals were used as carcinogens, 7, 12 dimethyl benz (a) anthracence (DMBA) was used as an initiator and 12-O-tetradecanoyl phorbol 13 acetate (TPA) was used as

promoter in the study. These chemicals had been obtained from Sigma Chemical Company. The DMBA (100µg/ml of acetone) was applied on the skin of the albino rats to test its effects as an initiator of skin cancer (Mughal 2005). This solution was prepared each time only a short time before its use and its temperature was maintained at 20-25 centigrade. Insulin syringe was used for the application of solution. TPA (20 µg/0.2 ml of acetone) was applied twice a week after DMBA to observe its role as a substance that promoted skin cancer (Bukhari, 2002; Mughal, 2005). The solution of TPA was prepared by mixing 1mg of dry TPA powder in 100ml of acetone. Acetone and dimethylformamide (DMF) 0.2ml were used as vehicles for all topically applied chemicals. However, only acetone and DMF was used on the skin of the rats belonging to the groups A and B to confirm its role as placebo.

After one week of quarantining and acclimatization of the rats, the back of each rat was shaved off hair (5x5 cm area) with electric clippers three days before the first dose was administered. TPA and DMBA are known carcinogens so high protective measures were taken during the application of drugs. All the animals are divided into four groups (A-D) twenty each. First and second (A and B) groups are acted as control and were treated biweekly topical application of acetone and DMF (dimethylformamide).

#### ***Particulars of lesion recorded***

Every week, loss of hair and gross morphological features such as ulcers were closely observed in each animal and if found, were then measured carefully with Vernier Calipers throughout the experiment. After the completion of fifteen weeks. The lesions and the surrounding skin of each animal was also closely examined (by a true cut fine needle biopsy) with a microscope. Applied to it to determine the extent of histopathological changes, such as papiloma malignant fibrous histiocytoma, atrophy, fibrosarcoma, chronic inflammation, squamous cell carcinoma in situ, extensive squamous cell carcinoma and osteoma at the end of the experiment. The lesions were then diagnosed according to the histopathological changes. Ether was used to anesthetize the rats. All the animals were sacrificed after giving the anesthesia in a glass jar after thirty weeks. After removing sections of the rats' dorsal skin, sections that

contained or surrounded the lesion were removed for further cutting. The cancerous and their surrounding tissues were washed two to three times with 10% formalin and were then used for histopathological studies.

### ***Histopathological studies***

To prepare the tissues for histopathological examination according to Gorden *et al.*, 1990; (Hopwood *et al.*, 1990; Stevens *et al.*, 1990) the following steps were taken: fixation which preserved cells in condition similar to the ones present during life, inhibited bacterial decomposition and also preserved loss of any easily diffusible substance by appropriate coagulation and strengthening of the tissues against the decomposing effects during various stages in tissue processing), gross examination and sectioning of the tissues: processing for the section: clearing: wax impregnation: embedding; storage of blocks; trimming of the wax blocks; section cutting; removal of paraffin wax; hydration; staining oiling; clearing and mounting. The identifications were ultimately got confirmed from an expert, Dr. Ehsan Hashmi, Pathology Department of King Edward Medical College, Lahore.

### ***Group A and B***

The animals of groups A and B were kept controlled. However, these animals received doses of acetone and dimethylformamide (DMF) the vehicles used for dilution of carcinogens and bis 3-Azophenyl-4-hydroxy-6-methyl-2H-pyran-2-one iron (II). (Table I).

### ***Group C***

The animals of this group were administered with DMBA at 100µg/ml of acetone topically as single dose on the shaved dorsum of the albino rat skin and TPA was given twice a week till 15 weeks to test the cancer inducing effects of DMBA and TPA (Table I).

### ***Group D***

Animals of Group D were given carcinogens (DMBA and TPA) in the same schedule as for other animals (Table I). In this group complex was given locally after 15 weeks of carcinogenesis in a dose 20µg/0.2ml twice a week for next 15 weeks to observe the response of locally applied given complex against chemical carcinogens. (Table I). In this group we saw the chemotherapeutic effect of complex. After completion of 30 weeks,

biopsies were taken to see the chemotherapeutic response of locally applied given complex against chemical carcinogenesis.

## RESULTS

### *Group A and B*

Forty albino rats that were used as control groups (A and B) in which biopsy of skin showed normal cells (Figure 4)

### *Group C*

In-group C all the chemical carcinogens (DMBA and TPA) were applied locally produced 90% lesions. Maximum number of lesions was encountered in this group (90%). All these animals received topical application of DMBA and TPA .In group C 13 animals developed benign lesions, which were epidermal hyperplasia (07) dysplasia (03) papilloma (04). There were (06) malignant lesions, which were squamous cell carcinoma in situ (02) squamous cell carcinoma (02) (Figure 3) and malignant fibrous histiocytoma (02) (Figure 2). Most of the rats have chronic inflammation and precancerous changes in early weeks. Hair loss was observed on specific area on third week where DMBA and TPA were applied locally and post application of DMBA and TPA slight bleeding and ulceration, which was not too deep, was observed at 15 week. Small sizes out growths were also observed (papilloma) at 15 week in the treated area.

### *Group D*

Thirteen animals developed benign lesions which were hyperplasia (08), papiloma (03) dysplasia (02). There were (06) malignant lesions in this group, which were squamous cell carcinoma in situ (03), squamous cell carcinoma (02) and malignant fibrous histiosytoma (01) (Figure 2) after 15 weeks of carcinogenesis (Table II). When chemotherapy was given 13 animals were cured which were suffering from benign lesions while squamous cell carcinoma in situ, squamous cell carcinoma and malginent fibrous hyperplasia were not cured however there were no death of any animal in this group. No further progression of malignancy was seen in this group.

## DISCUSSION

No tumor developed in the first and second group. However, albino rats belonging to the third group to whom no chemotherapy was given, all malignant tumors became worse and three animals bearing these malignant tumors died before the completion of experimental period. Our study suggested that use of iron complex decreases the risk of malignant conversion of benign tumors, because all benign tumors and pre-malignant lesions were cured with the use of bis 3-Azophenyl-4-hydroxy-6-methyl-2H-pyran-2-one iron (II). Our findings are consistent with Yuan *et al.*, (2004) they also used iron chelates as a anti-tumor. We suggested that if complex is given in early stage of tumor the results are 100% correct but in the case of malignant tumors we do not get any good results but still we are hopeful. This study concludes the chemotherapeutic effect against malignant tumors was not satisfactory; however it was not disappointing. There is immense scope for further research on these complexes. However, for the purpose of current study it was imperative to lay down certain parameters in order to achieve the desired results.

### Acknowledgment

The authors wish to thank the pathology department of King Edward Medical College University, Zoology department Government College University and Post Graduate Medical Center, Lahore for their help and value able suggestions during research.

**Table I: Group of Rats on the basis of treatments**

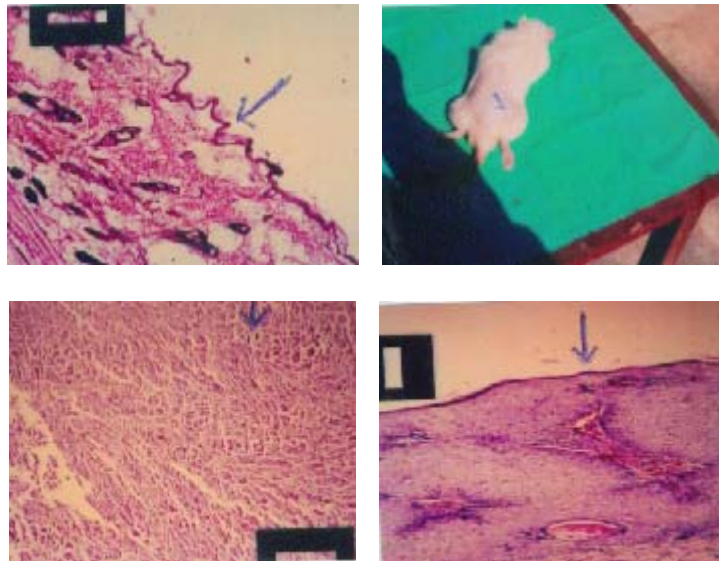
Group (30 Weeks)	Carcinogen (For 15 Weeks)				Curative (For 15 Weeks)	
	DMBA In acetone 100µg/ml		TPA In acetone 10 µg/ml After 2weeks of DMBA)		Complex in DMF 10 µg/ml (After 15 weeks of carcinogenesis)	
	Route	Schedule	Route	Schedule	Route	Schedule
A	Nil	Nil	Nil	Nil	Nil	Nil
B	Nil	Nil	Nil	Nil	Nil	Nil
C	Topical	Single dose	Topical	Twice a week till 15 weeks	Nil	Nil
D	Topical	Single dose	Topical	Twice a week till 15 weeks	Topical	Twice a week till 30 weeks

**Abbreviations used:** DMBA = 7, 12-dimethylbenz [a] anthracene; TPA =12-O-tetradecanoyl phorbol-13-acetate, Complex = bis 3-Azophenyl- 4-hydroxy-6-methyl-2h-pyran-2-one Iron (II).

**Table II: Distribution of lesions obtained in different Groups**

Groups N=20	Benign lesions				Malignant lesions				Total lesions (%)
	EPA	Pap	Dys	Total	SQCCIS	SQCC	MFH	Total	
A	Nil	Nil	Nil	Nil	Nil	Nil	Nil	Nil	0%
B	Nil	Nil	Nil	Nil	Nil	Nil	Nil	Nil	0%
C	7	4	3	13	2	2	2	6	19 (90%)
D (before complex)	8	3	2	13	3	2	1	6	19 (90%)
D(after complex)	Nil	Nil	Nil	Nil	3	2	1	6	5 (25%)

**Abbreviations used:** EPH: Epidermal hyperplasia, Pap: papilloma, Dys: dysplasia, SQCCIS: Squamous cell carcinoma in site, SQCC: squamous cell carcinoma, MFH: Malignant fibrous histiocytoma, Complex = bis 3-Azopheny1- 4-hydroxy-6-methy1-2H-pyran-2-one Iron (II).



**Figure 1:** Photograph showing papiloma (arrow) in an animal taking 7, 12-dimethylbenze (a) anthracene and 12-O-tetradecanoyl phorbol 13-acetate.

**Figure 2:** Photomicrograph showing histology of malignant fibrous histiocytoma (arrow) (H & E X 100).

**Figure 3:** Photomicrograph showing (arrow) histology of squamous cell carcinoma (arrow) (H&EX100) stage II grade-1.

**Figure 4:** Photomicrograph showing normal cells (arrow) in the skin of rat (h & e, x100).

## REFERENCES

- BHATTI, M. H., ALI, S., KHOKHAR M N., SYED, M. M., HASANAN. K, AND MALIK A. 2001. Synthesis, Characterization and Biological Studies of Some Metal (II) Complexes With 4-(P-Chlorophenyl)-2 Phenyl-5-Thiazoleacetic Acetic. *J. Chem. Soc. Pak.*, **23**: 35-38
- BUKHARI, S. M. H., SHAHZAD, S. Q. NAEEM, S. QYRESHI, G. R, AND NAVEED, I. A., 2002. A. Role of Chemical Carcenogens in Epithelial and Mesenchymal Neoplasm with Tumor Initiation-Promotion Protocol and the effect of 13-Cis Retinoic acid in chemoprevention. *JCPSP.*, **12**: 302-306.
- CHOHAN, Z. H., PERVAZ. H., SCOZOFAVA, A. AND SUPURAN, C. T., 2003. Antibacterial Co (II) Complexes of Benzothiazole-Derived Compounds. *J. Chem. Soc. Pak.*, **25**: 308-313.
- DOLLET, H. H., AND SORENSON. J. R. J., 1985. Historic uses of copper compounds in medicine, Trace Elements in Medicine, **2**: pp 80-87.
- GORDON, K.C. *Tissue processing in:* (Edd). 1990. *The theory and Practice of Histological Techniques*. Bancroft. JD, AND Steven A., Churchill Living Stone, Edinburgh pp. 43-45.
- HOPWOOD, D. Fixation and fixative In: BANCROFT, J. D, AND STEVEN A, (Edd). 1990. *The Theory and Practice of Histological Techniques.*, Churchill Living Stone., Edinburgh pp: 21-42.
- JUN, Y. DAVID. B. L. AND RICHARDSON, D. R., 2004. Novel di-2-pyridal-derived iron chelators with marked and selective antitumor activity in vitro and vivo assessment. *Blood*, **104**: 1450-1458.
- KALSOOM, A., MAZAHAR, M., ALI, S., CHOUDRY, M. I. AND MOLLOY, K C., 1996. Synthesis Characterization and Biological Activity of Diorganotin Complexes of 1,3 propandione and 1-phenyl-1,3 Butanedione. *J. Chem. Soc. Pakistan* **18**: 320-325.
- LEONG, A. AND. LEONG, G. W., 1989. Cancer explained causes, diagnosis treatment and prevention. P.G. Publishing, Pvt. Ltd, Singapore, pp: 170-190.
- REHMAN, S. U., CHOHAN, Z. H., GULNAZ F. AND SUPURAN, C. T., 2005. *In-vitro* antibacterial, antifungal and cytotoxic activities of some coumarins and their metal complexes. *J Enz. Inhib. Med.*, **0**:1-8.
- ROSENBERG, B. AND CAMP. L. V., 1970, Successful Regression of Large Solid Sarcoma 180 Tumor by Platinum compounds. *Cancer Res.*, **30**: 1799-1802.



- SHAHID, S., IQBAL J., HUMA R., 2005. Synthesis Characterization and Biological Activity of Some Derivatives of Triacetic Lactone and Their Metal-(II) Complexes. *J. Nat. Sci. Math.*, **45**: 1-14
- SIDDIQ, M. and PRAIL, P. F. G. 1982. Derivatives of 4-Hydroxy-6-methyl-pyran 2-one. (Triacetic lactone). *J. Chem. Soc. Pak.*, **4**: 81-87.
- STEVEN, A., 1990 The haematoxyline. In: *The theory and practice of Histological Techniques*. (eds. Bancroft J. D., Steven. A.) Churchill Living Stone, Edinburgh. 107-118.

(Received: 20 November, 2005; Revised: 15 February, 2006)