



Research Article

# Vulnerability of Three Days Old Chick Embryos to Permethrin Induced Toxicities

Shagufta Andleeb\*<sup>1</sup>, Fariha Zahid<sup>1</sup>, Noor-ul-Ain<sup>1</sup>, Yousra Nisar<sup>1</sup>, Chaman Ara<sup>2</sup>

<sup>1</sup>Division of Science & Technology, Department of Zoology, University of Education, Township Lahore, Pakistan.

<sup>2</sup>Department of Zoology, University of the Punjab, Lahore, Pakistan.

## Article History

Received: November 11, 2017

Revised: April 04, 2018

Accepted: April 14, 2017

Published: May 15, 2018

## Authors' Contributions

SA conceived the concept, supervised and executed the research. FZ, NA and YN performed the experimental work. CA did statistical analysis and wrote the manuscript.

## Keywords

Permethrin, *Gallus domesticus*, Teratogenicity, Embryotoxicity

**Abstract** | Agricultural and domestic use of permethrin, a pyrethroid insecticide, has led to intoxication of varying intensities in non target organisms including human. In present study, teratogenicity and embryotoxicity of permethrin was tested in developing chick (*Gallus domesticus*). Different concentrations of permethrin (0, 5, 10 and 20ppm) were prepared in sterilized distilled water. These doses were injected into eggs on 3<sup>rd</sup> day while recovery of embryos was done on 7<sup>th</sup> day of incubation. Disrupted embryos with microcephaly, hydrocephaly, short neck, micromelia, amelia, micrognathia, agnathia, cataract, ectopicardis, omphalocele, axis distortion, anencephaly, anophthalmia, microphthalmia, phocomelia with reduced body weight and crown-rump length in all dose groups were obtained. Adverse histological changes appeared in the form of disrupted and malformed visceral organs, vertebral bone and spina bifida as compared to control. The findings of this study clearly indicate that permethrin is potentially toxic to developing chicks, especially the highest concentrations used in the study.

**To cite this article:** Andleeb, S., Zahid, F., Noor-ul-Ain, Nisar, Y. and Ara, C., 2018. Vulnerability of three days old chick embryos to permethrin induced toxicities. *Punjab Univ. J. Zool.*, **33(1)**: 47-53. <http://dx.doi.org/10.17582/pujz/2018.33.1.47.53>

## Introduction

Several disorders like cancers, infertility, and above all, birth defects are on the role of indiscriminate use of pesticides (Mostafalou and Abdollahi, 2017). Permethrin, a pyrethroid insecticide is widely used domestically and agriculturally for vector control (Khan *et al.*, 2012; Liénard *et al.*, 2013). It is used as anti-lice (Clark *et al.*, 2015) as well as house fly and cockroach control (Zhu *et al.*, 2016). Prenatal exposure to permethrin in human is found to be associated with activation of immune activity in cord blood (Neta *et al.*, 2011). Human body has always been at expense of the drug through skin, dermal, inhalation, and oral path (Nakamura *et al.*, 2007; Saieva *et al.*, 2004; Wei *et al.*, 2013). Non-dietary exposure is reported as most important among children (Zartarian *et al.*, 2012). The

drastic effects of multiple concentrations of permethrin to non-target organism have been documented in various studies. It is well known for inducing mitochondrial functional impairment, altered immune system and oxidative stress in adult rats (Falcioni *et al.*, 2010; Nasuti *et al.*, 2008). While, early life exposure of rats showed an increase in proinflammatory cytokines and changes in heart cells, liver and many other long term defects in adult age (Carlioni *et al.*, 2012; Fedeli *et al.*, 2013; Gabbianelli *et al.*, 2013; Nasuti *et al.*, 2014). A wide range of concentrations of permethrin (0.013-70ppm) is announced as gonadotoxic (Issam *et al.*, 2011; Mostafa *et al.*, 2016; Yuan *et al.*, 2010; Zhang *et al.*, 2008), while the other (2-75ppm) as neurotoxic (Frag *et al.*, 2006; Imanishi *et al.*, 2013; Nasuti *et al.*, 2013) for rat as well as mice. Mutagenic potential has been triggered in human lymphocytes (*in vitro*) by 50-200ppm of permethrin (Barrueco *et al.*, 1994). Even topical exposure of 5% permethrin in infants for the treatment of scabies has led to the metabolic acidosis (Goksugur *et al.*, 2015).

\*Corresponding author Dr. Shagufta Andleeb,  
[drshagufta@ue.edu.pk](mailto:drshagufta@ue.edu.pk), [s\\_andleeb@yahoo.com](mailto:s_andleeb@yahoo.com)

## Materials and Methods

Eighty fertilized eggs of *Gallus domesticus* were divided equally into four groups. Considering LD50 (676ppm) announced by Anwar *et al.* (2004), three groups were given different concentrations of permethrin i.e. 5, 10 and 20ppm prepared in distilled water. While, fourth group (C) was normal control (given 0ppm of permethrin). On 3<sup>rd</sup> day of incubation at 37±0.5°C, a small surface area of the eggshell was cleaned and sterilized with help of cotton and ethanol to make a small window. Following application of 0.1 ml of each dose of permethrin, window was sealed by a drop of molten paraffin wax. Later on, eggs were incubated over a layer of cotton cushion at 37±0.5°C at some distance from each other. Ventilators of the incubator were kept on for aeration. A water-filled beaker was kept inside to provide moisture. Eggs were rotated twice daily for proper development of the embryos. Following recovery on day 7 and subsequent fixation in Bouin's fluid, embryos were analyzed for different parameters like wet body weight, crown rump length and morphological anomalies. Histological study of embryos was done through serial sectioning (using paraffin wax) and hematoxylin and eosin staining. The slides were observed for histological study using microscope SWIFT (M4000-D) and photo-micrographed with the help of digital camera BESTSCOPE (BUC2-500C).

Ethical parameters set by ethical Committee University of the Punjab were observed during the study. The data are expressed as mean ± SEM. Statistical analysis is performed by one-way analysis of variance (ANOVA)-Tukey's multiple comparison test using Prism Graphpad 5.01 Software (San Diego, CA) to establish significant differences ( $p < 0.05$ ) among groups.

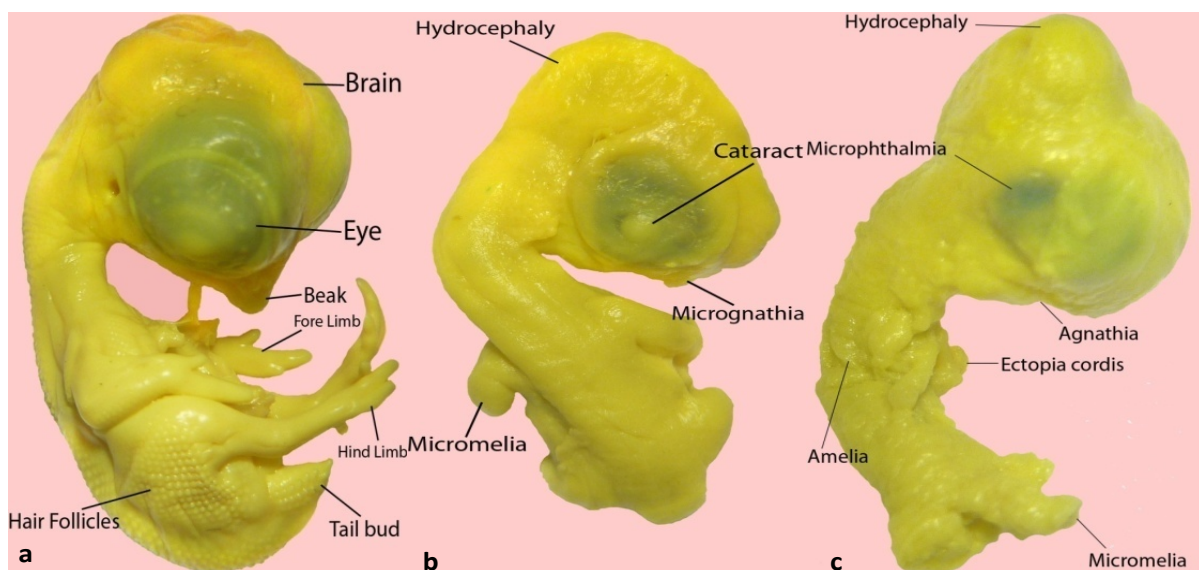
## Results

Embryos recovered from control group were well developed with normal body weight, size and organs. The average bodyweight, CR length of treated groups decreased significantly ( $p < 0.05$ ) than control (Table I). Embryos receiving 0ppm of permethrin were obtained with normal growth, while, those treated with 5 ppm of permethrin showed, hydrocephaly, micromelia, micrognathia, cataract, distorted axis (Figure 1a and b), amelia, short neck, microcephaly, agnathia (absence of beak), ectopiacordis, and omphalocoel. The other dose (10ppm) induced microcephaly, ectopiacordis, short neck, microphthalmia, and phocomelia in developing embryos, while embryos treated with highest dose (20ppm) were adversely affected showing various anomalies like amelia, microphthalmia, ectopiacordis, hydrocephaly, agnathia and omphalocoel (Figure 1c).

**Table I: Effect of different doses of permethrin on Body weight and CR length of chick embryos injected on 3<sup>rd</sup> and recovered on 7<sup>th</sup> day of incubation**

	C(0ppm)	5 ppm	10ppm	20ppm
Body weight(mg)	1424±95.45 <sup>a</sup>	1234.9±10.77 <sup>b</sup>	120.0±7.127 <sup>c</sup>	74.81±4.386 <sup>d</sup>
Crown rump length(mm)	23.56±0.8412 <sup>a</sup>	18.72±0.7037 <sup>b</sup>	10.62±0.1948 <sup>c</sup>	8.070±0.2707 <sup>d</sup>

Values are Mean±SEM of 20 replicates. Values not sharing common alphabet indicate significant difference ( $p < 0.05$ ) with each other [One way ANOVA-Tukey's multiple comparison test].



**Figure 1: Macrophotographs of chick embryos, recovered on day 7 of incubation, (a) from Control Group (0 ppm) (showing well developed body parts, (b) dose group 5ppm and (c) dose group 20ppm showing various morphological abnormalities like Hydrocephaly, distorted axis, Cataract, Microphthalmia, Micrognathia, Agnathia, Micromelia, Amelia, and Ectopiacordis.**



**Table II: Morphological abnormalities (%age) produced by permethrin in chick embryos injected on 3<sup>rd</sup> and recovered on 7<sup>th</sup> day of incubation**

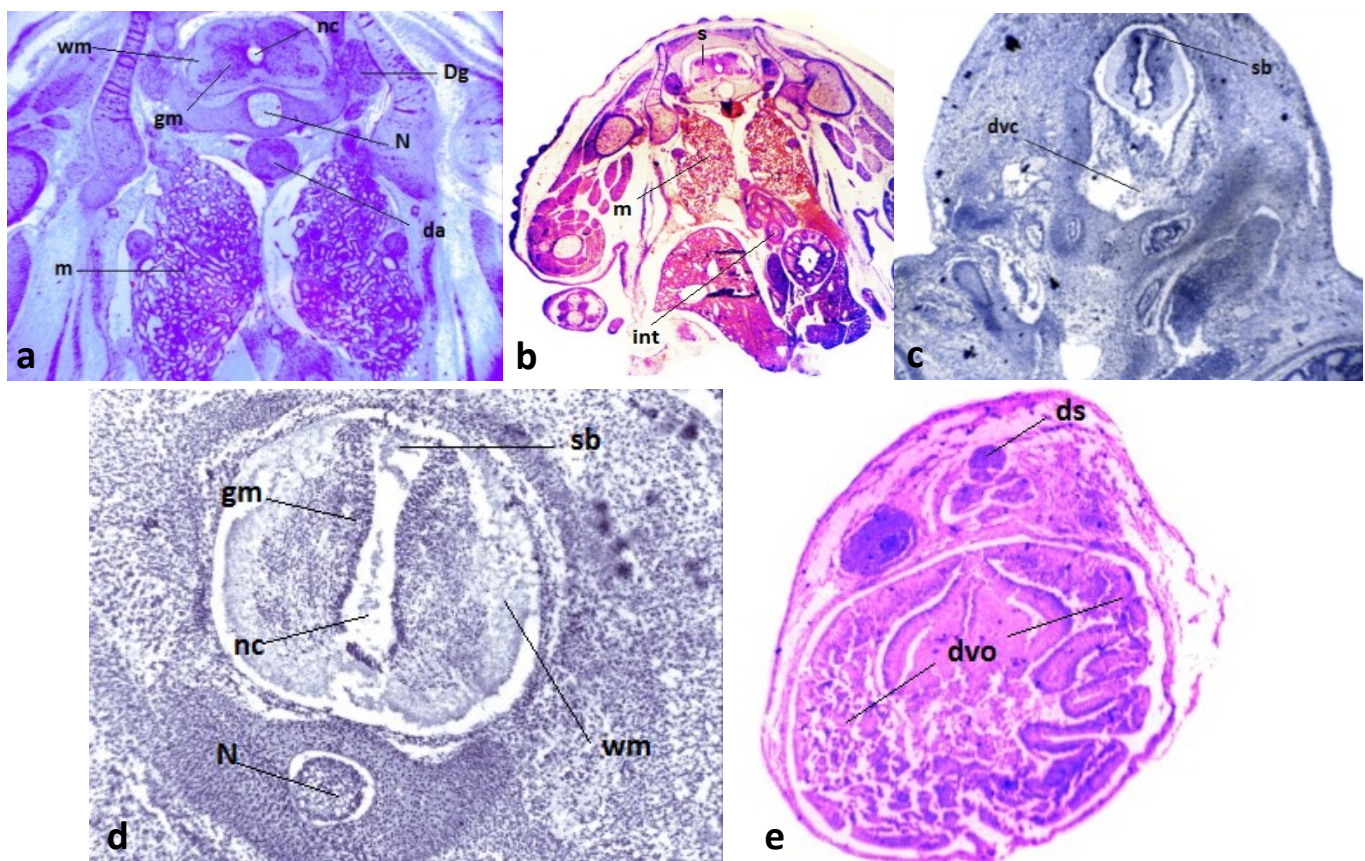
	C (0ppm)	5ppm	10ppm	20ppm
Hydrocephaly	0.00	75.00	80.00	95.00
Microcephaly	0.00	25.00	20.00	5.00
Agnathia	0.00	80.00	100.00	100.00
Micrognathia	0.00	20.00	0.00	0.00
Amelia	0.00	70.00	85.00	95.00
Micromelia	0.00	30.00	10.00	5.00
Phocomelia	0.00	0.00	5.00	0.00
Cataract	0.00	80.00	95.00	95.00
Microphthalmia	0.00	95.00	100.00	100.00
Ectopiacordis	0.00	95.00	100.00	100.00
Amniotic band	0.00	0.00	5.00	0.00

Among these malformations, hydrocephaly, agnathia (absence of beak), amelia, cataract, microphthalmia and ectopiacordis appeared in most of the embryos (Table II). Histological preparations of embryos from different dose groups revealed adverse effects of insecticide on de-

velopment of various body parts. Spina bifida, disrupted centrum of vertebral bone and malformed visceral organs were observed in highest dose group (Figure 2).

### Discussion

Reduced body weight and CR length, severe morphological as well as skeletal malformations, and disrupted viscera (Figure 1 and 2) in present study indicate the intense teratogenic potential of even lower concentrations of permethrin. Microphthalmia, agnathia and ectopiacordis appeared as the most prevalent malformation in all embryos (Table II). A comparable study in chick embryo came up with almost similar abnormalities including microphthalmia, axis distortion, spina bifida, hydrocephaly, exencephaly, ectopiacordis, gastroschisis, meningocephalocoe, with increased incidences of micromelia and micrognathia, reduced body weight and CR length in exposure to even lower doses (0.625, 1.25, 2.5 and 5ppm) of permethrin as compared to control (Andleeb *et al.*, 2014). Similar kind of abnormalities, including axial and appendicular skeletal structures have been observed in exposure to cypermethrin, a pyrethroid, in chick embryo too (Uggini *et al.*, 2012). Fetal exposure to insecticides is found to induce abnormal organogenesis including skeleton (Michal *et al.*, 1993).



**Figure 2: Macrophotographs of selected sections of 7 days old chick embryos treated with various doses of permethrin (a: control(0ppm), b: 5ppm, c: 10ppm, d-e: 20ppm) Labels:nc: neurocoel, wm: white matter, gm: gray matter, Dg: dorsal root ganglion, N: notochord, da: dorsal aorta, m: mesonephros, s: spinal cord, int: intestine, sb: spina bifida, dvc: disrupted vertebral column, ds: disrupted spinal cord, dvo: disrupted visceral organs (Hematoxylinand Eosin:4x).**

Permethrin may affect neurite outgrowth through interference with intracellular calcium regulation (Ferguson and Audesirk, 1990). In a study, pyrethroid exposure has been found to be associated negatively to neural and mental development of infants (Xue *et al.*, 2013).

In another study, higher concentrations of permethrin (50, 100 and 200 ppm) have notable effects on various enzymes, glucose, glycogen, total protein and lipids, cholesterol, uric acid, DNA and RNA contents of kidney of developing chick. In addition to these pronounced enzymatic and molecular changes, tubular necrosis, small sized and distorted glomeruli with blood cell infiltration, damaged endothelium of Bowman's capsule and epithelium of glomeruli were also encountered (Anwar, 2003a). Necrosis, pyknosis, increased sinusoidal spaces along with blood cell infiltration in 16 day old as well as newly hatched young chicks were documented on receiving the drug on day zero of incubation. Such findings indicate that pre-developmental exposure is quite lethal for developing liver (Anwar, 2003b; Anwar *et al.*, 2004; Anwar and Shakoori, 2010).

Permethrin is also a proven nephrotoxic and hepatotoxic in rat (Patrick-Iwuanyanwu and Charles, 2014). Significant decrease in weight of brain was observed in chick embryos as compared to heart and liver when treated with 5ppm permethrin (Alhifi, 2010). This teratogenic attribute of permethrin is may be by interfering the functioning of detoxifying enzymes (Ezeji *et al.*, 2012).

Insufficient comprehensive study on toxicity of permethrin in chick embryo, entertains probable assumptions for chick embryo regarding histopathological toxicities induced by permethrin, accomplished by peeping into toxic effects induced in other animals. Testicular damage, decrease in testis weight and serum testosterone concentrations in mice have been manifested owing to 25, 50 and 100ppm of permethrin (Jin *et al.*, 2012). Disrupted architecture, diminished count of mature sperm cells, wider luminal diameter, reduced interstitial spaces in testis (Omotoso *et al.*, 2014), and necrosis in addition to apoptosis in kidney has been characterized in rats in consequence of treatment with permethrin (Guvenc *et al.*, 2013). Dose-dependent effects have been reported in splenic as well as thymic cellularity among mice (Prater *et al.*, 2002). Such deformities and toxicities are debatable for humans too. Various biomarkers of permethrin like trans- and cis-3-(2,2-dichlorovinyl)-2, 2-dimethylcyclopropane-1-carboxylic acid metabolites (trans-DCCA, cis-DCCA), and 3-phenoxybenzoic acid (3-PBA) have been detected in urine even through inhalation (Ferland *et al.*, 2015) and once inside the blood circulation, it may cross the placenta and target various organs of fetus (Borkhardt *et al.*, 2003). Moreover, hardly fifty percent is eliminated after 84hrs of oral administration of very small amount (Ratelle *et al.*, 2015), and may cause neurodegeneration leading to Par-

kinson's disease (Nasuti *et al.*, 2017).

Various mechanisms of toxicities of pyrethroids have been presented (Ray and Fry, 2006; Soderlund, 2012). Oxidative stress is the mechanism of action of many developmental toxicants (Hansen, 2006) including pyrethroids (Zepeda-Arce *et al.*, 2017) and embryo is the most vulnerable to oxidative stress (Dennerly, 2007). Moreover, electron transfer, unfolded protein response, apoptosis leading to disrupted endocrine functioning and central nervous system, DNA attack, enzyme inhibition, interference with hormonal action, proteins, and mitochondria, and unavailability of ATP, GTP, and detoxifying enzymes are other possible mechanisms exploited by insecticides as well as pesticides to disrupt the normal development (Kovacic and Somanathan, 2006; Kupsco and Schlenk, 2015; Ngoula *et al.*, 2012; Zhang *et al.*, 2017). Unfolded protein response (UPR) mediators and signaling proteins respond efficiently to toxicants and also play important role in prenatal development (Cornejo *et al.*, 2013). Endoplasmic reticulum stress due to UPR is well known to induce apoptosis in cells in response to reactive oxygen species (ROS) generated by toxicants (Gong *et al.*, 2017).

## Conclusions

It is concluded from the present study that permethrin is highly toxic and teratogenic, as it has been found to cause severe skeletal and visceral abnormalities in chick embryo. Therefore, misuse of the insecticide and associated health risks is challenging for the government and health department to educate the workers involved in its formulation and handling, and create awareness among household as well as agricultural users regarding dose application and precautionary measurements.

## Acknowledgements

We are highly thankful to Department of Zoology, University of the Punjab for providing animal house facility.

## Conflict of Interest

All authors have not any kind of conflict of interest.

## References

- Alhifi, M., 2010. Oxidative stress in chick embryo brain, liver and heart treated with mixture of dimethoate and methidathion. *Sci. Technol. Vis.*, **6**: 32-38.
- Andleeb, S., Kalsoom, S., Ghazanfar, S., Shaukat, S. and Hanif, S., 2014. Developmental anomalies induced by permethrin in *Gallus domesticus*. *Punjab Uni. J. Zool.*, **29**: 63-67.



- Anwar, K.K., Ali, S.S. and Shakoori, A.R., 2004. Effect of a single sublethal dose of permethrin on the development of liver in chick embryo. *Pakistan J. Zool.*, **36**: 59-68.
- Anwar, K., 2003a. Effect of permethrin treatment on the kidney of newly hatched chick (*Gallus domesticus*). *Pak. J. Appl. Sci.*, **3**: 317-330. <https://doi.org/10.3923/jas.2003.317.330>
- Anwar, K., 2003b. Toxicological effect of single treatment of permethrin injected into the eggs on 0<sup>th</sup> day of incubation on the liver of newly hatched chick. *Online J. Biol. Sci.*, **3**: 660-673. <https://doi.org/10.3923/jbs.2003.660.673>
- Anwar, K. and Shakoori, A.R., 2010. Cypermethrin toxicity in the liver of developing chick embryo. *Pakistan J. Zool.*, **42**: 725-733.
- Barrueco, C., Herrera, A., Caballo, C. and De La Pena, E., 1994. Induction of structural chromosome aberrations in human lymphocyte cultures and CHO cells by permethrin. *Teratog. Carcinog. Mutagen.*, **14**: 31-38. <https://doi.org/10.1002/tcm.1770140105>
- Borkhardt, A., Wilda, M., Fuchs, U., Gortner, L. and Reiss, I., 2003. Congenital leukaemia after heavy abuse of permethrin during pregnancy. *Arch. Dis. Childhood-Fet. Neon.*, **88**: 436-437.
- Carloni, M., Nasuti, C., Fedeli, D., Montani, M., Amici, A., Vadhana, M.S. and Gabbianelli, R., 2012. The impact of early life permethrin exposure on development of neurodegeneration in adulthood. *Exp. Gerontol.*, **47**: 60-66. <https://doi.org/10.1016/j.exger.2011.10.006>
- Clark, J. M., Yoon, K.S., Kim, J.H., Lee, S.H. and Pittendrigh, B.R., 2015. Utilization of the human louse genome to study insecticide resistance and innate immune response. *Pesticide Biochem. Physiol.*, **120**: 125-132. <https://doi.org/10.1016/j.pestbp.2014.11.008>
- Cornejo, V.H., Pihan, P., Vidal, R.L. and Hetz, C., 2013. Role of the unfolded protein response in organ physiology: lessons from mouse models. *IUBMB. Life.*, **65**: 962-975. <https://doi.org/10.1002/iub.1224>
- Dennery, P.A., 2007. Effects of oxidative stress on embryonic development. *Bir. Def. Res. C. Emb. To.*, **81**: 155-162. <https://doi.org/10.1002/bdrc.20098>
- Ezeji, E.U., Anyalogbu, E.A., Ezejiolor, T.N. and Udensi, J.U., 2012. Determination of reduced glutathione and glutathione S-transferase of poultry birds exposed to permethrin insecticide. *Am. J. Biochem.*, **2**: 21-24. <https://doi.org/10.5923/j.ajb.20120203.01>
- Falcioni, M.L., Nasuti, C., Bergamini, C., Fato, R., Lenaz, G. and Gabbianelli, R., 2010. The primary role of glutathione against nuclear DNA damage of striatum induced by permethrin in rats. *Neurosci.*, **168**: 2-10. <https://doi.org/10.1016/j.neuroscience.2010.03.053>
- Farag, A.T., Goda, N.F., Mansee, A.H. and Shaaban, N.A., 2006. Effects of permethrin given before mating on the behavior of F1-generation in mice. *Neurotoxicology*, **27**: 421-428. <https://doi.org/10.1016/j.neuro.2005.12.001>
- Fedeli, D., Carloni, M., Nasuti, C., Gambini, A., Scocco, V. and Gabbianelli, R., 2013. Early life permethrin exposure leads to hypervitaminosis D, nitric oxide and catecholamines impairment. *Pestic. Biochem. Physiol.*, **107**: 93-97. <https://doi.org/10.1016/j.pestbp.2013.05.010>
- Ferguson, C.A. and Audesirk, G., 1990. Effects of DDT and permethrin on neurite growth in cultured neurons of chick embryo brain and *Lymnaea stagnalis*. *Toxicol. In Vitro.*, **4**: 23-30. [https://doi.org/10.1016/0887-2333\(90\)90005-E](https://doi.org/10.1016/0887-2333(90)90005-E)
- Ferland, S., Cote, J., Ratelle, M., Thuot, R. and Bouchard, M., 2015. Detailed urinary excretion time courses of biomarkers of exposure to permethrin and estimated exposure in workers of a corn production farm in Quebec, Canada. *Ann. Occup. Hyg.*, **59**: 1152-1167. <https://doi.org/10.1093/annhyg/mev059>
- Gabbianelli, R., Palan, M., Flis, D.J., Fedeli, D., Nasuti, C., Skarydova, L. and Ziolkowski, W., 2013. Imbalance in redox system of rat liver following permethrin treatment in adolescence and neonatal age. *Xenobio.*, **43**: 1103-1110. <https://doi.org/10.3109/00498254.2013.796427>
- Goksugur, S. B., Karatas, Z., Goksugur, N., Bekdas, M. and Demircioglu, F., 2015. Metabolic acidosis in an infant associated with permethrin toxicity. *Pediatr. Dermatol.*, **32**: 15-17. <https://doi.org/10.1111/pde.12473>
- Gong, J., Wang, X.Z., Wang, T., Chen, J.J., Xie, X.Y., Hu, H., Yu, F., Liu, H.L., Jiang, X.Y. and Fan, H.D., 2017. Molecular signal networks and regulating mechanisms of the unfolded protein response. *J. Zhejiang. Univ. Sci.*, **18**: 1-14. <https://doi.org/10.1631/jzus.B1600043>
- Guvenc, D., Kabak, Y., Atmaca, E., Aksoy, A. and Guvenc, T., 2013. Examination of caspase-dependent apoptotic and necrotic changes in rat kidney exposed to different doses of permethrin. *Biotech. Histochem.*, **88**: 76-85. <https://doi.org/10.3109/10520295.2012.736637>
- Hansen, J.M., 2006. Oxidative stress as a mechanism of teratogenesis. *Bir. Def. Res. C. Emb. To.*, **78**: 293-307. <https://doi.org/10.1002/bdrc.20085>
- Imanishi, S., Okura, M., Zaha, H., Yamamoto, T., Akanuma, H., Nagano, R., Shiraishi, H., Fujimaki, H. and Sone, H., 2013. Prenatal exposure to permethrin influences vascular development of fetal brain and adult behavior in mice offspring. *Environ. Toxicol.*, **28**: 617-629. <https://doi.org/10.1002/tox.20758>
- Issam, C., Zohra, H., Monia, Z. and Hassen, B.C., 2011. Effects of dermal sub-chronic exposure of

- pubescent male rats to permethrin (PRMT) on the histological structures of genital tract, testosterone and lipoperoxidation. *Exp. Toxicol. Pathol.*, **63**: 393-400. <https://doi.org/10.1016/j.etp.2010.02.016>
- Jin, Y., Liu, J., Wang, L., Chen, R., Zhou, C., Yang, Y., Liu, W. and Fu, Z., 2012. Permethrin exposure during puberty has the potential to enantioselectively induce reproductive toxicity in mice. *Environ. Int.*, **42**: 144-151. <https://doi.org/10.1016/j.envint.2011.05.020>
- Khan, A., Ahmad, L. and Khan, M.Z., 2012. Hemato-biochemical changes induced by pyrethroid insecticides in avian, fish and mammalian species. *Int. J. Agric. Biol.*, **14**: 834-842.
- Kovacic, P. and Somanathan, R., 2006. Mechanism of teratogenesis: electron transfer, reactive oxygen species, and antioxidants. *Bir. Def. Res. C. Emb. To.*, **78**: 308-325. <https://doi.org/10.1002/bdrc.20081>
- Kupsco, A. and Schlenk, D., 2015. Oxidative stress, unfolded protein response, and apoptosis in developmental toxicity. *Int. Rev. Cell Mol. Biol.*, **317**: 1-66. <https://doi.org/10.1016/bs.ircmb.2015.02.002>
- Liènard, E., Bouhsira, E., Jacquiet, P., Warin, S., Kaltsatos, V. and Franc, M., 2013. Efficacy of dinotefuran, permethrin and pyriproxyfen combination spot-on on dogs against *Phlebotomus perniciosus* and *Ctenocephalides canis*. *Parasitol. Res.*, **112**: 3799-3805. <https://doi.org/10.1007/s00436-013-3568-z>
- Michal, F., Grigor, K.M., Negro-Vilar, A. and Skakkebaek, N. E., 1993. Impact of the environment on reproductive health: Executive summary. *Environ. Health Perspect.*, **101**: 159-167. <https://doi.org/10.2307/3431390>  
<https://doi.org/10.1289/ehp.93101s2159>
- Mostafa, H.E., Abd El-Baset, S.A., Kattaia, A.A., Zidan, R.A. and Al Sadek, M.M., 2016. Efficacy of naringenin against permethrin-induced testicular toxicity in rats. *Int. J. Exp. Pathol.*, **97**: 37-49. <https://doi.org/10.1111/iep.12168>
- Mostafalou, S. and Abdollahi, M., 2017. Pesticides: an update of human exposure and toxicity. *Arch. Toxicol.*, **91**: 549-599. <https://doi.org/10.1007/s00204-016-1849-x>
- Nakamura, Y., Sugihara, K., Sone, T., Isobe, M., Ohta, S. and Kitamura, S., 2007. The in vitro metabolism of a pyrethroid insecticide, permethrin, and its hydrolysis products in rats. *Toxicology*, **235**: 176-184. <https://doi.org/10.1016/j.tox.2007.03.016>
- Nasuti, C., Brunori, G., Eusepi, P., Marinelli, L., Ciccocioppo, R. and Gabbianelli, R., 2017. Early life exposure to permethrin: A progressive animal model of Parkinson's disease. *J. Pharmacol. Toxicol. Meth.*, **83**: 80-86. <https://doi.org/10.1016/j.vascn.2016.10.003>
- Nasuti, C., Carloni, M., Fedeli, D., Gabbianelli, R., Di, S.A., Serafina, C.L., Silva, I., Domingues, V. and Ciccocioppo, R., 2013. Effects of early life permethrin exposure on spatial working memory and on monoamine levels in different brain areas of pre-senescent rats. *Toxicology*, **303**: 162-168. <https://doi.org/10.1016/j.tox.2012.09.016>
- Nasuti, C., Fattoretti, P., Carloni, M., Fedeli, D., Ubaldi, M., Ciccocioppo, R. and Gabbianelli, R., 2014. Neonatal exposure to permethrin pesticide causes lifelong fear and spatial learning deficits and alters hippocampal morphology of synapses. *J. Neurodev. Disord.*, **6**: 7. <https://doi.org/10.1186/1866-1955-6-7>
- Nasuti, C., Falcioni, M.L., Nwankwo, I.E., Cantalamessa, F. and Gabbianelli, R., 2008. Effect of permethrin plus antioxidants on locomotor activity and striatum in adolescent rats. *Toxicology*, **251**: 45-50. <https://doi.org/10.1016/j.tox.2008.07.049>
- Neta, G., Goldman, L.R., Barr, D., Apelberg, B.J., Witter, F.R. and Halden, R.U., 2011. Fetal exposure to chlordane and permethrin mixtures in relation to inflammatory cytokines and birth outcomes. *Environ. Sci. Technol.*, **45**: 1680-1687. <https://doi.org/10.1021/es103417j>
- Ngoula, F., Ngouateu, O.B., Kana, J.R., Defang, H.F., Watcho, P., Kamtchouing, P. and Tchoumboue, J., 2012. *Insecticides-Advances in Integrated Pest Management*, (ed. F. Perveen), In Tech, pp. 429-456.
- Omoso, G.O., Onanuga, I.O. and Ibrahim, R., 2014. Histological effects of permethrin insecticide on the testis of adult wistar rats. *Ibnosina J. Med. Biomed. Sci.*, **6**: 125-129. <https://doi.org/10.4103/1947-489X.210373>
- Patrick-Iwuanyanwu, K.C. and Charles, I.A., 2014. Biochemical and histological changes in liver and kidney in male Wistar albino rats following exposure to Solignum: A permethrin-containing wood preservative. *J. Xenobio.*, **4**: 40-45. <https://doi.org/10.4081/xeno.2014.4596>
- Prater, M.R., Gogal, R.M., Jr., Blaylock, B.L., Longstreth, J. and Holladay, S.D., 2002. Single-dose topical exposure to the pyrethroid insecticide, permethrin in C57BL/6N mice: Effects on thymus and spleen. *Food Chem. Toxicol.*, **40**: 1863-1873. [https://doi.org/10.1016/S0278-6915\(02\)00163-1](https://doi.org/10.1016/S0278-6915(02)00163-1)
- Ratelle, M., Cote, J. and Bouchard, M., 2015. Toxicokinetics of permethrin biomarkers of exposure in orally exposed volunteers. *Toxicol. Lett.*, **232**: 369-375. <https://doi.org/10.1016/j.toxlet.2014.12.003>
- Ray, D.E. and Fry, J.R., 2006. A reassessment of the neurotoxicity of pyrethroid insecticides. *Pharmacol. Ther.*, **111**: 174-193. <https://doi.org/10.1016/j.pharmthera.2005.10.003>
- Saieva, C., Aprea, C., Tumino, R., Masala, G., Salvini, S., Frasca, G., Giurdanella, M.C., Zanna, I., Decarli, A. and Sciarra, G., 2004. Twenty-four-hour urinary excretion of ten pesticide metabolites in healthy adults in two different areas of Italy (Florence and Ragusa). *Sci. Tot. Environ.*, **332**: 71-80.

- Soderlund, D.M., 2012. Molecular mechanisms of pyrethroid insecticide neurotoxicity: Recent advances. *Arch. Toxicol.*, **86**: 165-181. <https://doi.org/10.1016/j.scitotenv.2004.02.026>
- Uggini, G.K., Patel, P.V. and Balakrishnan, S., 2012. Embryotoxic and teratogenic effects of pesticides in chick embryos: a comparative study using two commercial formulations. *Environ. Toxicol.*, **27**: 166-174. <https://doi.org/10.1002/tox.20627>
- Wei, B., Isukapalli, S.S. and Weisel, C.P., 2013. Studying permethrin exposure in flight attendants using a physiologically based pharmacokinetic model. *J. Exp. Sci. Environ. Epidemiol.*, **23**: 416-427. <https://doi.org/10.1038/jes.2013.12>
- Xue, Z., Li, X., Su, Q., Xu, L., Zhang, P., Kong, Z., Xu, J. and Teng, J., 2013. Effect of synthetic pyrethroid pesticide exposure during pregnancy on the growth and development of infants. *Asia Pac. J. Pub. Health.*, **25**:72-79. <https://doi.org/10.1177/1010539513496267>
- Yuan, C., Wang, C., Gao, S.Q., Kong, T.T., Chen, L., Li, X.F., Song, L. and Wang, Y.B., 2010. Effects of permethrin, cypermethrin and 3-phenoxybenzoic acid on rat sperm motility in vitro evaluated with computer-assisted sperm analysis. *Toxicol. In Vitro.*, **24**: 382-386. <https://doi.org/10.1016/j.tiv.2009.11.001>
- Zartarian, V., Xue, J., Glen, G., Smith, L., Tulve, N. and Tornero-Velez, R., 2012. Quantifying children's aggregate (dietary and residential) exposure and dose to permethrin: Application and evaluation of EPA's probabilistic SHEDS-Multimedia model. *J. Expo. Sci. Environ. Epidemiol.*, **22**: 267-273. <https://doi.org/10.1038/jes.2012.12>
- Zepeda-Arce, R., Rojas-Garcia, A.E., Benitez-Trinidad, A., Herrera-Moreno, J.F., Medina-Diaz, I.M., Barron-Vivanco, B.S., Villegas, G.P., Hernandez-Ochoa, I., Solis Heredia, M.J. and Bernal-Hernandez, Y.Y., 2017. Oxidative stress and genetic damage among workers exposed primarily to organophosphate and pyrethroid pesticides. *Environ. Toxicol.*, **32**: 1754-1764. <https://doi.org/10.1002/tox.22398>
- Zhang, Q., Zhang, Y., Du, J. and Zhao, M., 2017. Environmentally relevant levels of lambda-cyhalothrin, fenvalerate, and permethrin cause developmental toxicity and disrupt endocrine system in zebrafish (*Danio rerio*) embryo. *Chemosph.*, **185**: 1173-1180. <https://doi.org/10.1016/j.chemosphere.2017.07.091>
- Zhu, F., Lavine, L., O'neal, S., Lavine, M., Foss, C. and Walsh, D., 2016. Insecticide Resistance and Management Strategies in Urban Ecosystems. *Insects*, **7**: 2. <https://doi.org/10.3390/insects7010002>
- Zhang, S.Y., Ueyama, J., Ito, Y., Yanagiba, Y., Okamura, A., Kamijima, M. and Nakajima, T., 2008. Permethrin may induce adult male mouse reproductive toxicity due to cis isomer not trans isomer. *Toxicology*, **248**: 136-141. <https://doi.org/10.1016/j.tox.2008.03.018>